


The features and clinical outcomes of inflammatory bowel disease associated with autoimmune pancreatitis

A greater awareness is needed

Maria Cristina Conti Bellocchi, MD^{a,*} , Eugenio Marconato, MD^a, Laura Lamonaca, MD^b, Martina Cattani Mottes, MD^a, Rachele Ciccocioppo, MD, PhD^a, Silvia Carrara, MD^b, Nicolò de Pretis, MD, PhD^a, Armando Gabrielli, MD^a, Stefano Francesco Crinò, MD^a, Luca Frulloni, MD, PhD

Abstract

The prevalence of inflammatory bowel disease (IBD) has been described in 5% to 40% of autoimmune pancreatitis (AIP) patients. The aim of our study was to evaluate the prevalence, endoscopic features, and outcome of IBD in association with AIP.

A retrospective analysis including all consecutive patients with AIP and a histological diagnosis of IBD from 2010 to 2020 was performed. Demographical data, AIP, and IBD features, as well as clinical course, were recorded.

Among 267 AIP patients, 45 were diagnosed with ulcerative colitis (UC) (27 men, mean age 31.6), all with a diagnosis of type 2 AIP. The most frequent presentation of AIP was acute pancreatitis (55.5%). Both diffuse (51.1%) and focal (48.9%) pancreatic involvement were observed. The AIP relapse rate was 11.1% over a mean follow-up of 55 months. In 69% of patients, the interval time between the diagnosis of AIP and UC was <1 year. When UC was present at AIP onset, UC was in clinical remission in 50% of patients. Fecal calprotectin levels, when available, were elevated in 86.6% of these patients. Mostly, mild–moderate pancolitis was initially diagnosed (55.5%). During follow-up, escalation therapy for UC was required in 40% of patients after a mean time of 45 months. Two patients (4.4%) underwent colectomy.

The prevalence of UC in AIP patients was 17%. Mild pancolitis with a low rate of colectomy was found. Greater awareness is needed to avoid a delayed diagnosis of UC, and the dosage of fecal calprotectin levels could have a role in this setting.

Abbreviations: AIP = autoimmune pancreatitis, FC = fecal calprotectin, GELs = granulocytic epithelial lesions, IBD = inflammatory bowel disease, ICDC = International Consensus Diagnostic Criteria, UC = ulcerative colitis.

Keywords: autoimmune pancreatitis, clinical outcome, diagnosis, inflammatory bowel diseases, ulcerative colitis

1. Introduction

The association between autoimmune pancreatitis (AIP) and inflammatory bowel disease (IBD) has been described in 5% to

40% of patients^[1–6] with a predominant prevalence of ulcerative colitis (UC). According to the International Consensus Diagnostic Criteria (ICDC),^[7] the diagnosis of IBD in AIP patients allows the implementation of the classification of the disease as type 2 AIP, even if histology is not definitive. Type 2 AIP is histologically characterized by granulocytic epithelial lesions (GELs) and usually affects young patients with normal serological IgG4 levels. Classifying AIP as type 2 is relevant since its clinical outcome is significantly less aggressive in terms of disease relapse than that of type 1 AIP. Furthermore, it allows the exclusion of other extrapancreatic manifestations of IgG4-related disease, which are associated with type 1 AIP only.^[8]

A possible common immune-mediated mechanism has been suggested to explain the association of AIP and IBD. Similar histological features between type 2 AIP GELs and cryptic abscesses, typical of UC, suggest a common pathogenetic mechanism.^[9] A recent review about the role of “lymphocyte homing”, that is, the modulation of lymphocyte migration through increased the expression of vascular addressins in chronic inflammation demonstrated important analogies between AIP and UC.^[10]

Although this association is known, very few data about the clinical features and outcome of UC associated with type 2 AIP are available.

Therefore, the study aimed to evaluate the prevalence, clinical, endoscopic, and histological features and clinical outcomes of UC in patients suffering from AIP.

Editor: Raffaele Pezilli.

The authors have no funding and conflicts of interest to disclose.

All data generated or analyzed during this study are included in this published article [and its supplementary information files].

^a Department of Medicine, Gastroenterology and Digestive Endoscopy Unit, Pancreas Institute, University of Verona, Verona, Italy, ^b Digestive Endoscopy Unit, Division of Gastroenterology, Humanitas Research Hospital, Rozzano, Italy.

* Correspondence: Maria Cristina Conti Bellocchi, Department of Medicine, Gastroenterology and Digestive Endoscopy Unit, The Pancreas Institute, University Hospital of Verona, P.le L.A. Scuro 10, 37134 Verona, Italy (e-mail: mcristina.contibellocchi@gmail.com, mariacristina.contibellocchi@aovr.veneto.it).

Copyright © 2022 the Author(s). Published by Wolters Kluwer Health, Inc. This is an open access article distributed under the terms of the Creative Commons Attribution-Non Commercial License 4.0 (CCBY-NC), where it is permissible to download, share, remix, transform, and buildup the work provided it is properly cited. The work cannot be used commercially without permission from the journal.

How to cite this article: Bellocchi MC, Marconato E, Lamonaca L, Mottes MC, Ciccocioppo R, Carrara S, de Pretis N, Gabrielli A, Crinò SF, Frulloni L. The features and clinical outcomes of inflammatory bowel disease associated with autoimmune pancreatitis: a greater awareness is needed. *Medicine* 2022;101:4 (e28602).

Received: 15 October 2021 / Received in final form: 27 December 2021 / Accepted: 29 December 2021

<http://dx.doi.org/10.1097/MD.00000000000028602>

2. Materials and methods

A retrospective study from a prospectively maintained database was performed. All consecutive AIP patients, definitive or probable according to the ICDC,^[7] followed at the Pancreas Institute, referral Center for pancreatic diseases at University of Verona, from 2010 to 2020 were included. The prospective database and all its retrospective evaluations were approved by our local ethics committee (protocol number 393CESC), and this study was conducted according to the Declaration of Helsinki.

Medical records were reviewed to identify patients with a histological diagnosis of IBD according to the European Crohn's and Colitis Organization (ECCO) guidelines.^[11]

Demographical data, clinical characteristics of AIP, including IgG4 levels (1–2 or >2 upper normal limits), therapy, and outcome were recorded for the selected patients. Endoscopic findings, induction and maintenance therapy, and outcomes (need for escalation therapy or surgery) for IBD were also reported. In addition, fecal calprotectin (FC) levels at the time of AIP and IBD diagnoses were recorded, if available. For IBD histological evaluation, only patients with index colonoscopy performed in our center were included. For study purposes, 3 groups of patients were considered concerning the time of diagnosis of AIP and IBD (previously, concomitantly, or after UC diagnosis).

Cross-sectional imaging and laboratory findings were reviewed by 2 expert clinicians (MCCB and LF), and in the case of a lack of recent outpatient visits, a telephone interview was performed to verify the interval health history. The date of the last clinical follow-up was defined as the last contact. Patients with >3 years without clinical information were considered drop-outs.

Descriptive statistics were used to analyze patient characteristics. Data are expressed as frequencies with percentages or means \pm standard deviations.

3. Results

Two hundred sixty-seven AIP patients (188 males and 79 females, mean age 55.4 years) were evaluated. Overall, 167 type 1, 54 type 2, and 46 type not otherwise specified (NOS) were reported. Fifty-four patients with a recorded diagnosis of IBD or with symptoms suggestive of bowel inflammation were found. Nine patients were excluded due to a lack of definitive histological diagnosis of IBD. Therefore, 45 patients (27M and 18 F, mean age 37.7 ± 12.9 years) were included in the final analysis, all with a diagnosis of UC and therefore classified as type 2 AIP. The prevalence of UC was 16.8% among all AIP patients and 83.3% among type 2 AIP patients. The study flowchart is shown in Figure 1.

The diagnosis of type 2 AIP was definitive by histology in 3 out of 45 patients (6.7%) only, in 2 by Endoscopic Ultrasound-guided fine needle biopsy (EUS-FNB), and in 1 based on pancreatic specimens after surgery (distal splenopancreatectomy was performed for a focal pancreatic lesion). Therefore, 42 patients had a diagnosis of probable type 2 AIP.

The baseline characteristics of the included patients are summarized in Table 1.

At diagnosis, diffuse or focal AIP was observed on imaging in 23 (51.1%) and 22 (48.9%) patients, respectively. The clinical presentation was mainly acute pancreatitis ($n=25$, 55.5%). Nine patients (20%) presented with jaundice, 8 (17.8%) with serum lipase or amylase elevation, and 3 (6.7%) with weight loss. IgG4

dosage was available for 41 of 45 patients and was normal in all patients. All patients were treated with corticosteroids (1 mg/kg for the first 2–4 weeks) and then tapered by 5 mg/week. Disease relapse was instrumentally documented by imaging after steroids in 5 patients (11.1%), 4 of whom were successfully retreated with steroids and 1 patient with immunosuppressant therapy (azathioprine) after steroid-induced remission. The characteristics of AIP are presented in Table 2.

The diagnosis of UC was made at a mean age of 31.6 ± 12.5 years.

The diagnosis of UC was made before the clinical onset of AIP in 18 patients (40%), 12 of whom were within 1 year before and 6 of whom were >1 year before (mean time of 55 months, range 24–112). At the time of diagnosis of AIP, UC was in remission in 9 patients (50%), whereas 8 patients (44.4%) had active disease, and 1 (5.6%) underwent total colectomy with ileostomy many years before. These patients were on oral/topical mesalamine therapy, azathioprine (AZA), and infliximab in 15, 1, and 1 patients, respectively. The last patient had no ongoing treatment for IBD because of previous colectomy. In the only patient on AZA therapy at AIP onset, AZA had been started >3 years before.

A diagnosis of UC was formulated concomitantly with AIP in 12 patients (26.6%).

Finally, AIP was first diagnosed in 15 patients (33.3%), 7 of whom were within 1 year and 8 >1 year (mean 52 months, range 22–156). These patients classified by the ICDC as suffering from type NOS AIP were switched to type 2 AIP after the diagnosis of UC.

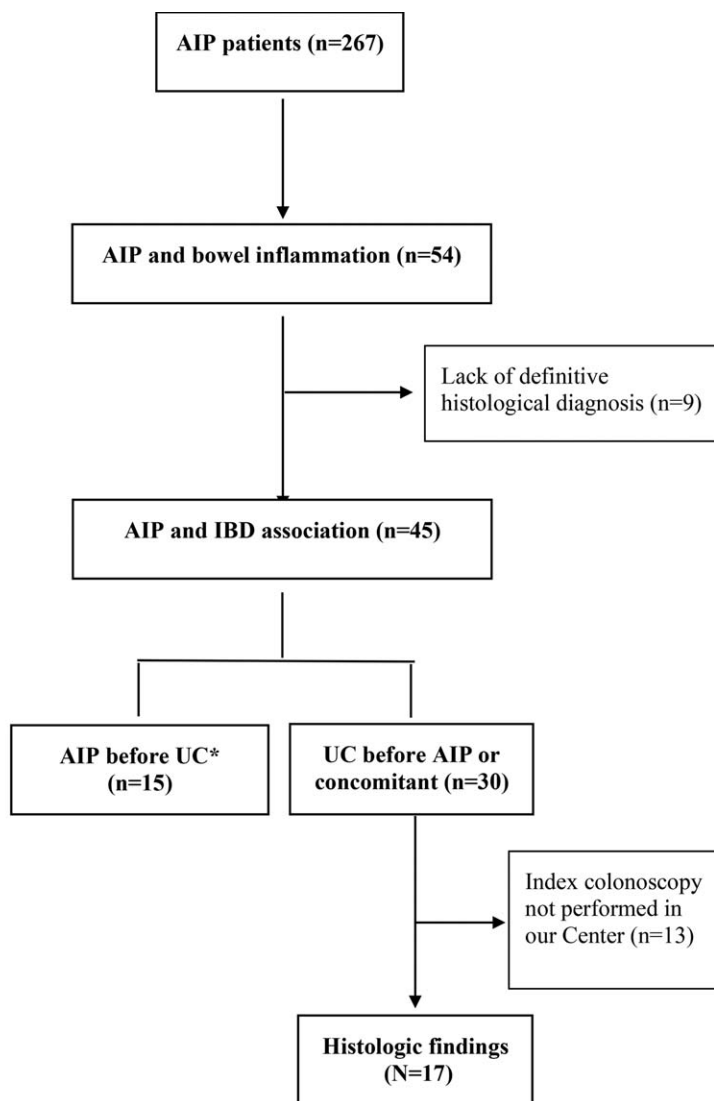
Overall, approximately 70% of patients developed AIP and UC concomitantly or within 1 year.

The fecal calprotectin level at AIP diagnosis was available in 15 out of 19 patients with concomitant or subsequent (<1 year) diagnosis of UC, and it was elevated (>250 $\mu\text{g/g}$ of feces) (mean 1433 ± 2104) in 13 of them (86.6%). Therefore, diagnosis was achieved based on symptoms and elevated calprotectin levels in 9 patients, symptoms without dosage or with normal calprotectin levels in 6 patients, and with only calprotectin elevation without symptoms in 4 patients.

The endoscopic appearance of UC at diagnosis was mild–moderate, mostly extensive, colitis according to the Montreal classification.^[12] Typical endoscopic UC with continuous colonic involvement was reported in 24 patients (53.3%), whereas discontinuous involvement was present in 14 patients (31.1%). No clear description of endoscopic features was reported in 7 out of 45 patients.

The endoscopic activity index (endoscopic Mayo score) was registered in the final report of 36 patients. Only 1 patient presented with severe score (Mayo 3) left-sided colitis and required infliximab as induction therapy. At UC onset, oral/topical mesalamine, steroids and infliximab were used to induce remission in 20 (44.4%), 24 (53.4%), and 1 (2.2%) patients, respectively. At the last follow-up, the maintenance therapy was oral/topical mesalamine, azathioprine, and infliximab in 23 patients (51%), 8 (17.8%), and 10 (22.2%), respectively. Azathioprine was prescribed for AIP relapse in 1 patient. Infliximab was used after a mean interval from UC diagnosis of 45 months. Two patients (4.4%) underwent colectomy, in 1 patient before the diagnosis of AIP.

Clinical, laboratory, and endoscopic details of IBD are listed in Table 3.



* Patients with AIP previously diagnosed were excluded in order to avoid that steroid therapy could influence histological findings.

Figure 1. Flowchart of the study. *Patients with AIP previously diagnosed were excluded in order to avoid that steroid therapy could influence histological findings.

In the subgroup of 17 patients with index colonoscopy performed in our center, an inflammatory infiltrate and cryptitis were commonly observed, with an inhomogeneous distribution

of inflammation reported in approximately 50% of patients. Sparse mucosal IgG4-positive plasma cells in immunochemistry were found in 3 out of 8 patients (37.5%), in all 3 with <10/HPF. Both endoscopic and histological findings are shown in Table 4.

Mean age of patients	37.7 ± 12.9 (range 19–73)
Sex	
Male/female	27/18
Smoking	
Yes/no	15/30
Drinking	
Yes/no	0/45
Familiarity	
Pancreatic disease	2 (4.4%)
IBD	6 (13.3%)
Median follow-up (mo)	55 (6–142)

AIP = autoimmune pancreatitis, IBD = inflammatory bowel disease.

4. Discussion

In the present study, we investigated our large prospectively maintained database of AIP patients and included 45 patients with histologically confirmed IBD. UC was the only type of IBD found, and its prevalence was approximately 17% and 83% in the overall AIP patients and type 2 AIP patients, respectively. To date, a few small studies have reported the prevalence of IBD in AIP patients, and the epidemiological characteristics were similar to those of our study.^[13–16] However, in the study by Buechter et al,^[6] a significantly higher prevalence of females in AIP2 patients were reported (68.8%) compared to the present study (40%). Probably the majority of female AIP2 patients reported in literature is biased due to the low number of patients. In the

Table 2
Characteristics of AIP (n = 45).

Mean age at diagnosis (yr)	32.1 ± 12.5 (range 16–69)
Mean duration of disease (yr)	6.2 ± 3.2 (range 1–14)
AIP diagnosis (according to ICDC)	
Definitive type 2	3 (6.7%)
“Probable” type 2	42 (93.3%)
AIP location	
Diffuse enlargement	23 (51.1%)
Focal enlargement	22 (48.9%)
Head	11 (50%)
Body	4 (18.2%)
Tail	7 (31.8%)
AIP presentation	
Acute pancreatitis	25 (55.5%)
Jaundice	9 (20%)
Pancreatic hyperenzymemia	8 (17.8%)
Weight loss	3 (6.7%)
Serum IgG4*	
Normal value	41 (100%)
1–2 × upper limit of normal value	0
>2 × upper limit of normal value	0
Calprotectin levels at AIP diagnosis†	
Normal	2
Increased	13
AIP relapse	5 (11.1%)
Maintenance therapy (AZA)	1 (2.2%)

AIP = autoimmune pancreatitis, ICDC = International Consensus Diagnostic Criteria.

* IgG4 levels were available in 41 patients.

† Calprotectin dosage was performed in 15 patients.

multicentre analysis by Hart et al^[2] and in the multicentric study by Lorenzo et al,^[13] where a great number of subjects is included, the prevalence of male patients was quite similar (55% and 48%).

All 45 patients had mild–moderate UC, with involvement of the colon above the splenic flexure in 55.5% of patients. This finding reflects existing data indicating 35% to 75% pancolitis among AIP-UC patients^[13,15–17] Interestingly, in our experience, symptoms were mild despite disease extent, and 4 patients were completely asymptomatic. The diagnosis in asymptomatic patients was made possible by colonoscopy performed after discovering increased levels of FC, which is routinely tested in AIP patients at our center. This policy probably led us to observe early modifications of colon involvement in UC patients. Since UC was never seen in type 1 AIP, we may suggest evaluation of FC levels at diagnosis or during follow-up of type 2 or type NOS AIP, even in asymptomatic patients.

A low need for escalation therapy was documented over the years, and the colectomy rate was quite low at 4.4% (2 patients) over a mean follow-up time of 55 months from the diagnosis of UC. This frequency was similar to a Korean study (7.3%) with a follow-up of 48 months^[18] but different from French data, which reported a higher rate of colectomy (22%) over a long follow-up (68 months).^[13]

Histological evaluation of the colon was performed in a subgroup of patients who underwent colonoscopy at our center. According to the ECCO guidelines, microscopic diagnosis of UC is based on widespread crypt architectural distortion, a diffuse transmucosal inflammatory infiltrate with basal plasmacytosis, eventually associated with an active component causing cryptitis and crypt abscesses.^[11] We found an inhomogeneous distribution of inflammation in colon biopsy specimens in 8 out of 17 patients, and a “patchy” infiltrate with typical features of UC in different

Table 3
Characteristics of IBD (n = 45).

Mean age at diagnosis (yr)	31.6 ± 12.5 (range 13–69)
Mean duration of disease (yr)	6.4 ± 3.2 (range 1–14)
Type of IBD	
Ulcerative colitis	45 (100%)
Crohn disease	0
Time between AIP and UC diagnosis	
Concomitant	12 (26.7%)
UC before AIP	18 (40%)
<1 yr	12
>1 yr	6
AIP before UC	15 (33.3%)
<1 yr	7
>1 yr	8
UC extent at diagnosis	
Proctitis	8 (17.8%)
Left-sided colitis	12 (26.6%)
Extensive colitis	25 (55.5%)
Endoscopic Mayo score at diagnosis*	
Mayo 1	13 (36.1%)
Mayo 2	22 (61.1%)
Mayo 3	1 (2.7%)
Macroscopic distribution on endoscopy	
Inhomogeneous	14 (31.1%)
Continuous	24 (53.3%)
Unavailable data	7 (15.6%)
Fecal calprotectin levels at IBD diagnosis	
Elevated	8 (17.8%)
Not available data	37 (82.2%)
Extraintestinal manifestation	1 (2.2%)
Treatment at last follow-up	
Oral/topical mesalamine	23 (51.1%)
Azathioprine	8 (17.8%)
Biologics	10 (22.2%)
Colectomy	2 (4.4%)

AIP = autoimmune pancreatitis, IBD = inflammatory bowel disease, UC = ulcerative colitis.

* Endoscopic Mayo Score of first colonoscopy was available in 36 patients.

Table 4
Endoscopic and histologic findings on index colonoscopy of UC-AIP patients (n = 17).

Disease extent	
Proctitis	2 (14.3%)
Left-sided colitis	5 (35.7)
Pancolitis	7 (50%)
Endoscopic Mayo Score	
Mild	5 (35.7%)
Moderate	9 (64.3%)
Severe	0
Histologic findings	
Inflammatory infiltrate	16 (94.1%)
Cryptitis	14 (82.3%)
Architectural distortion	9 (52.9%)
Crypt abscesses	9 (52.9%)
Basal plasmacytosis	8 (47%)
Mucin depletion	7 (41.1%)
IgG4 infiltrate*	3 (37.5%)
Inhomogenous inflammation	8 (47%)

AIP = autoimmune pancreatitis, UC = ulcerative colitis.

* Performed in 8/17 patients.

bowel segments was observed only in 50% of patients. Early modification of UC, or a new subtype of IBD, could be postulated. Only specifically designed prospective studies

investigating the evolution of these findings may clarify their meaning.

IgG4 immunostaining on colonic specimens was performed in 7 of 14 patients, and a low number of plasma cells (<10/HPF [High Power Field]) was found to be positive in 3 patients. Few studies have evaluated IgG4 infiltration in the colonic mucosa of patients with and without AIP. However, IgG4-positive plasma cells were also described in IBD patients without AIP.^[19,20] Rebours et al^[21] suggested that this finding reflects the general inflammatory context more than specific AIP-related disorders.

All patients included in the current study were diagnosed with type 2 AIP. Based on the ICDC, 2 findings are needed to reach a definitive diagnosis of type 2 AIP: typical histology (ie, absent or scanty IgG4-positive cells and GELs or granulocytic infiltrate) on either pancreatic core needle biopsies or surgical specimens and the presence of IBD. However, preoperative acquisition of specimens suitable for histological evaluation is difficult using standard EUS fine needles for aspiration (EUS-FNA)^[22,23] and cannot be achieved by papilla of Vater biopsies. Consequently, the presence of IBD remains crucial for diagnosis. Indeed, in addition to an effective response to steroids, a “probable” type 2 AIP diagnosis can be formulated. As expected, in the current study, the diagnosis of type 2 AIP was “probable” in almost all patients (42 out of 45) according to the ICDC,^[7] with only 2 diagnoses based on EUS-guided histology. However, the rate of definitive diagnosis with emerging EUS fine-needle biopsy devices (end-cutting forward-acquiring needles) will probably rise in the near future.^[24,25] The Mayo Clinic demonstrated that patients with both probable and definitive diagnoses have similar demographic profiles and disease-related outcomes.^[26] Therefore, a definitive histologic diagnosis of type 2 AIP is probably not needed in this clinical setting (presence of UC) but can be required in patients with NOS-type AIP. In a recent study, a relevant percentage (17.4%) of reclassification from NOS to type 2 AIP was reported, adding the onset of IBD after a median time of 17 months.^[27] Therefore, a close follow-up of type NOS AIP patients is suggested after the end of steroid treatment to make a diagnosis of IBD as soon as possible.

The AIP diffuse or focal phenotype was equally represented among our patients (51% and 49%, respectively). Conflicting data are available in the literature. Eastern studies describe focal pancreatic involvement in 21%^[28] and 17%^[15] of patients. However, these data come from small case series (7 and 6, respectively). In contrast, the French GETAID-AIP study including 91 patients^[13] reported the focal form in 68% of patients. Therefore, in patients with a history of UC, a diagnosis of AIP should be suspected in the presence of a pancreatic mass (focal). However, despite the higher probability of AIP, pancreatic biopsy is strongly recommended to confirm the diagnosis and exclude malignancy in any patient before using steroids.

French authors postulated that systemic inflammation during active IBD may promote the onset of AIP. They supported this hypothesis with evidence showing that 80% of patients had a previous or concomitant diagnosis of IBD, and approximately 70% had active disease at AIP onset. However, our findings do not seem to support this hypothesis. Indeed, in the present study, 68% of patients had a previous or concomitant diagnosis of UC, but only 44% had an active disease (50% in remission and 5.6% with previous colectomy at AIP onset).

In our study, the most common clinical presentation was acute pancreatitis (55.5%), despite being lower than previous

studies,^[13,28] and asymptomatic pancreatic enzyme elevation was observed in 8 patients (18%). Pancreatic hyperenzymemia has been observed in 14% of IBD patients,^[29] and it is still unknown how many of these patients eventually develop AIP or other pancreatic diseases. We believe that elevation of pancreatic enzymes, with or without acute typical pain, should be accurately investigated in UC patients by Magnetic Resonance Imaging (MRI) to confirm AIP or other pancreatic diseases. Moreover, the diagnosis of AIP is clinically relevant in patients with UC because it prevents drug withdrawal in the suspicion of drug-induced pancreatitis, particularly if azathioprine is treated.

All but one of our patients was successfully treated with steroids. The only patient who did not receive corticosteroids had a focal AIP misdiagnosed as pancreatic cancer and underwent pancreatic surgery.

Approximately 11% of patients relapsed, which is consistent with previous studies with similar follow-up reporting a relapse rate ranging between 0% and 34%.^[28,30]

Our study has some limitations, including the retrospective design and unavailability of all histological colonic samples for revision. Moreover, a “definitive” type 2 AIP was diagnosed in only 3 patients due to a lack of histology.

Despite these limitations, our cohort of patients with AIP represents the largest single-center experience thus far and reports new findings that have the potential to change clinical management. UC associated with type 2 AIP affects mostly young patients, is usually mild, and rarely requires escalation therapy or colectomy. A peculiar histological pattern was observed, with an inhomogeneous distribution of inflammation, both macroscopically and microscopically. Greater awareness is needed to diagnose IBD early when AIP occurs. The role of calprotectin levels in this context seems to be helpful, but it needs to be further investigated in prospective studies.

Author contributions

Conceptualization: Maria Cristina Conti Bellocchi, Luca Frulloni.

Data curation: Maria Cristina Conti Bellocchi, Eugenio Marconato, Laura Lamona, Martina Cattani Mottes.

Formal analysis: Maria Cristina Conti Bellocchi, Stefano Francesco Crinò.

Methodology: Maria Cristina Conti Bellocchi, Stefano Francesco Crinò.

Supervision: Rachele Ciccocioppo, Silvia Carrara, Armando Gabbrielli, Stefano Francesco Crinò.

Visualization: Nicolo' De Pretis.

Writing – original draft: Maria Cristina Conti Bellocchi.

Writing – review & editing: Maria Cristina Conti Bellocchi, Luca Frulloni.

References

- Frulloni L, Scattolini C, Falconi M, et al. Autoimmune pancreatitis: differences between the focal and diffuse forms in 87 patients. *Am J Gastroenterol* 2009;104:2288–94.
- Hart PA, Kamisawa T, Brugge WR, et al. Long-term outcomes of autoimmune pancreatitis: a multicentre, international analysis. *Gut* 2013;62:1771–6.
- Maire F, Le Baleur Y, Rebours V, et al. Outcome of patients with type 1 or 2 autoimmune pancreatitis. *Am J Gastroenterol* 2011;106:151–6.
- Kamisawa T, Chari ST, Giday SA, et al. Clinical profile of autoimmune pancreatitis and its histological subtypes: an international multicenter survey. *Pancreas* 2011;40:809–14.

- [5] Fritz S, Bergmann F, Grenacher L, et al. Diagnosis and treatment of autoimmune pancreatitis types 1 and 2. *Br J Surg* 2014;101:1257–65.
- [6] Buechter M MP, Heinemann FM, Lindemann M, et al. Outcome and genetic factors in IgG4-associated autoimmune pancreatitis and cholangitis: a single center experience. *Gastroenterol Res Pract* 2017; 2017:6126707.
- [7] Shimosegawa T, Chari ST, Frulloni L, et al. International consensus diagnostic criteria for autoimmune pancreatitis: guidelines of the International Association of Pancreatology. *Pancreas* 2011;40:352–8.
- [8] Ikeura T, Manfredi R, Zamboni G, et al. Application of international consensus diagnostic criteria to an Italian series of autoimmune pancreatitis. *United European Gastroenterol J* 2013;1:276–84.
- [9] Tsen A AY, Rosenkranz L. Autoimmune pancreatitis and inflammatory bowel disease: an updated review. *J Clin Gastroenterol* 2017;51:208–14.
- [10] Sakai Y KM. Lymphocyte 'homing' and chronic inflammation. *Pathol Int* 2015;65:344–54.
- [11] Magro F LC, Driessen A, Ensari A, et al. European Society of Pathology (ESP); European Crohn's and Colitis Organisation (ECCO). European consensus on the histopathology of inflammatory bowel disease. *J Crohns Colitis* 2013;7:827–51.
- [12] Morishima T KH, Ohno E, Yamamura T, et al. Prospective multicenter study on the usefulness of EUS-guided FNA biopsy for the diagnosis of autoimmune pancreatitis. *Gastrointest Endosc* 2016;84:241–8.
- [13] Lorenzo D, Maire F, Stefanescu C, et al. Features of autoimmune pancreatitis associated with inflammatory bowel diseases. *Clin Gastroenterol Hepatol* 2018;16:59–67.
- [14] Roque Ramos L, DiMaio CJ, Sachar DB, et al. Autoimmune pancreatitis and inflammatory bowel disease: case series and review of the literature. *Dig Liver Dis* 2016;48:893–8.
- [15] Park SH, Kim D, Ye BD, et al. The characteristics of ulcerative colitis associated with autoimmune pancreatitis. *J Clin Gastroenterol* 2013; 47:520–5.
- [16] Ravi K, Chari ST, Vege SS, et al. Inflammatory bowel disease in the setting of autoimmune pancreatitis. *Inflamm Bowel Dis* 2009;15:1326–30.
- [17] Jae Bock Chung, Seon Joo Kim, Myung-Hwan Kim, et al. Korea-Japan symposium for autoimmune pancreatitis. *Gut Liver*. 2007; 1:186–7.
- [18] Kim JW HS, Park SH, Song TJ, et al. Clinical course of ulcerative colitis patients who develop acute pancreatitis. *World J Gastroenterol* 2017; 23:3505–12.
- [19] Kuwata G KT, Koizumi K, Tabata T, et al. Ulcerative colitis and immunoglobulin G4. *Gut Liver* 2014;8:29–34.
- [20] Topal F, Saritas Yuksel E, Ekinici N, et al. The prevalence of IgG4-positive plasma cell infiltrates in inflammatory bowel disease patients without autoimmune pancreatitis. *Turk J Gastroenterol* 2014;25: 558–62.
- [21] Rebours V, Le Baleur Y, Cazals-Hatem D, et al. Immunoglobulin G4 immunostaining of gastric, duodenal, or colonic biopsies is not helpful for the diagnosis of autoimmune pancreatitis. *Clin Gastroenterol Hepatol* 2012;10:91–4.
- [22] Morishima T, Kawashima H, Ohno E, et al. Prospective multicenter study on the usefulness of EUS-guided FNA biopsy for the diagnosis of autoimmune pancreatitis. *Gastrointest Endosc* 2016;84: 241–8.
- [23] Chari ST, Smyrk TC, Levy MJ, et al. Diagnosis of autoimmune pancreatitis: the Mayo Clinic experience. *Clin Gastroenterol Hepatol* 2006;4:1010–6. quiz 934.
- [24] Chhoda A, Rustagi T. EUS-guided needle biopsy for autoimmune pancreatitis. *Clin J Gastroenterol* 2020;13:669–77.
- [25] Crinò SF, Di Mitri R, Nguyen NQ, et al. Eus-guided fine-needle biopsy with or without rapid on-site evaluation for diagnosis of solid pancreatic lesions: a randomized controlled non-inferiority trial. *Gastroenterology* 2021;161: 899.e5–909.e5.
- [26] Hart PA, Levy MJ, Smyrk TC, et al. Clinical profiles and outcomes in idiopathic duct-centric chronic pancreatitis (type 2 autoimmune pancreatitis): the Mayo Clinic experience. *Gut* 2016;65:1702–9.
- [27] de Pretis N, Vieceli F, Brandolese A, et al. Autoimmune pancreatitis not otherwise specified (NOS): clinical features and outcomes of the forgotten type. *Hepatobiliary Pancreat Dis Int* 2019;18:576–9.
- [28] Ueki T, Kawamoto K, Otsuka Y, et al. Prevalence and clinicopathological features of autoimmune pancreatitis in Japanese patients with inflammatory bowel disease. *Pancreas* 2015;44:434–40.
- [29] Ramos LR SD, DiMaio CJ, Colombel JF, Torres J. Inflammatory bowel disease and pancreatitis: a review. *J Crohns Colitis* 2016;10: 95–104.
- [30] Oh D, Song TJ, Moon SH, et al. Type 2 autoimmune pancreatitis (idiopathic duct-centric pancreatitis) highlighting patients presenting as clinical acute pancreatitis: a single-center experience. *Gut Liver* 2019; 13:461–70.