[Downloaded free from http://www.eusjournal.com on Sunday, April 1, 2018, IP: 87.15.71.110]

Endoscopic ultrasound features of pancreatic schwannoma

Stefano Francesco Crinò, Laura Bernardoni, Erminia Manfrin[1], Alice Parisi[1], Armando Gabbrielli
Department of Medicine, Unit of Digestive Endoscopy, The Pancreas Institute, University of Verona Hospital Trust, [1]Department of Diagnostics and Public Health, University of Verona Hospital Trust, Verona, Italy

A 59-year-old female underwent abdominal ultrasound for dyspepsia. A 2 cm pancreatic nodule was incidentally discovered. Computer tomography scanning confirmed a solid mass of the pancreatic uncinate process; at endoscopic ultrasound (EUS) examination, it appeared as a round, well-demarked, solid homogeneous, hypoechoic mass [Figure 1]. In contrast-enhanced EUS (CE-EUS) images, the lesion showed poor contrast intake, with a hypoenhanced pattern compared to the surrounding pancreatic parenchyma [Figure 2]. Fine-needle aspiration (FNA) with a standard 25G needle revealed spindle cells [Figure 3] that expressed S-100 protein, suggestive for schwannoma. Surgical enucleation was performed, and diagnosis was confirmed on a surgical specimen [Figure 4].

Pancreatic schwannoma is an extremely rare tumor. Complete descriptions of the EUS features or exhaustive EUS images are found in five reports[1-5] whereas the CE-EUS pattern is described in a single one[5] [Table 1].

Schwannomas are capsulated tumors that, at imaging, are generally round or oval and show well-defined margins. Histologically, schwannomas comprised two areas: Antoni A, characterized by packed spindle cells and a vascular component, and Antoni B, which is hypocellular and occupied by loose stroma. The latter area may be the subject of degenerative changes, such as cyst formation, hemorrhage, necrosis, and calcification.

Cystic degeneration is related to larger sizes and can affect the endosonographic appearance. When it is small (generally <2 cm), schwannoma can appear as a solid homogeneous lesion.[2,4] The vascular component of the Antoni A area is likely responsible for the poor contrast intake. In our case, as reported by Nishikawa *et al.*,[5] the lesion was hypoenhanced, compared to the surrounding pancreatic parenchyma; this feature is common to the pancreatic carcinoma from which schwannoma differs in the well-defined margins and the noninfiltrative behavior. Larger schwannomas with cystic changes mimic the whole spectrum of cystic pancreatic lesions. The preoperative diagnosis of cystic neuroendocrine tumor and of solid pseudopapillary neoplasm may be difficult. The

Access this article online

Quick Response Code:

Website: www.eusjournal.com

DOI: 10.4103/2303-9027.195873

This is an open access article distributed under the terms of the Creative Commons Attribution-NonCommercial-ShareAlike 3.0 License, which allows others to remix, tweak, and build upon the work non-commercially, as long as the author is credited and the new creations are licensed under the identical terms.

For reprints contact: reprints@medknow.com

How to cite this article: Crinò SF, Bernardoni L, Manfrin E, Parisi A, Gabbrielli A. Endoscopic ultrasound features of pancreatic schwannoma. Endosc Ultrasound 2016;5:396-8.

Address for correspondence
Dr. Stefano Francesco Crinò, Department of Medicine, Unit of Digestive Endoscopy, The Pancreas Institute, G. B. Rossi Hospital, University of Verona Hospital Trust, P.Le L.A. Scuro 10, 37134 Verona, Italy. E-mail: stefanocrino@hotmail.com
Received: 2016-07-11; **Accepted:** 2016-09-19

[Downloaded free from http://www.eusjournal.com on Sunday, April 1, 2018, IP: 87.15.71.110]

Table 1. Main endoscopic ultrasound features of reported pancreatic schwannomas

Case	Location	Size (mm)	Shape	Endosonographic appearance	Margins	CE-EUS	FNA, needle	FNA-IHC	Outcome
Mummadi, 2009	Body	70	Oval	Complex multilocular cyst	Well-defined	NA	NA	NA	Surgery
Li, 2009	Body	16	Round	Solid hypoechoic	Well-defined	NA	22G standard	S100	Surgery
Barresi, 2012	Head	70	Round	Complex multilocular cyst	Well-defined	NA	22G standard	S100	Surgery
Antonini, 2015	Neck	10	Round	Solid hypoechoic	Well-defined	NA	25G proCore	S100	Follow-up
Nishikawa, 2016	Body	20	Oval	Complex multilocular cyst	Well-defined	Hypovascular	25G proCore	S100	Follow-up
Current case	Uncinate	21	Round	Solid hypoechoic	Well-defined	Hypovascular	25G standard	S100	Surgery

CE-EUS: Contrast-enhanced endoscopic ultrasound, FNA: Fine-needle aspiration, NA: Not available, FNA-IHC: Immunohistochemical staining on FNA specimen

Figure 1. Linear endoscopic ultrasound demonstrating a solid, homogeneous, well-defined hypoechoic lesion in the uncinate process of the pancreas

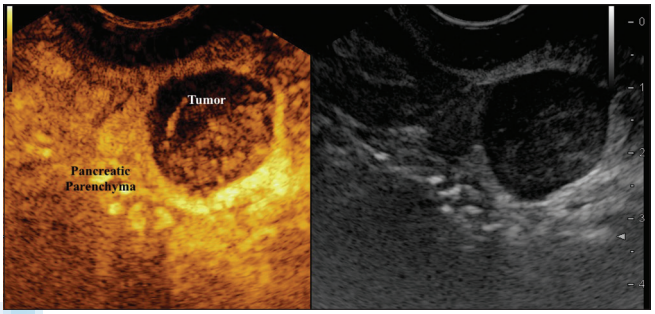

Figure 2. Contrast-enhanced endoscopic ultrasound showing a hypoenhanced pattern of the tumor compared with the surrounding pancreatic parenchyma

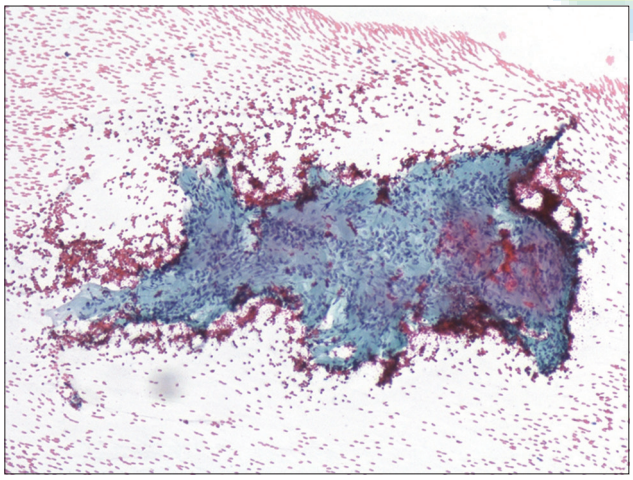

Figure 3. Endoscopic ultrasound-guided fine-needle aspiration specimen showing dense fibrillary substance with Antoni A palisading spindle-shaped cells (Papanicolaou, ×40)

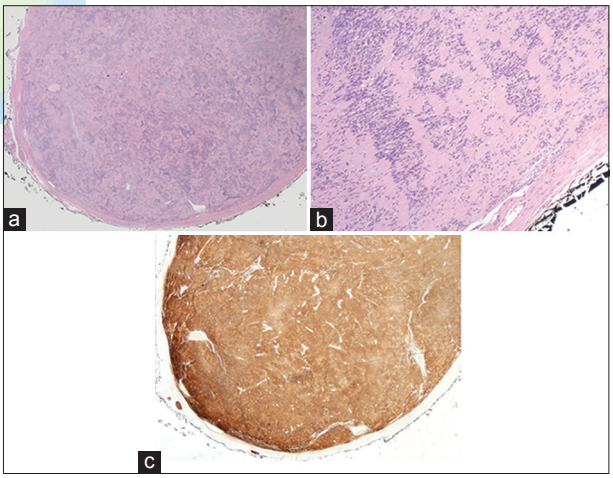

Figure 4. Surgical specimen histopathology: Solid nodular lesion, surrounded by a fibrous capsule (a), in which the typical hallmark of a schwannoma growth pattern of alternating Antoni A and B areas is clearly visible (b) (EE, ×10). S-100 protein is strongly expressed by schwannoma cells (c)

hypoenhanced pattern of schwannoma at CE-EUS may help achieve the diagnosis. Targeting the solid component during FNA is mandatory.

Financial support and sponsorship

Nil.

Conflicts of interest

There are no conflicts of interest.

REFERENCES

1. Mummadi RR, Nealon WH, Artifon EL, *et al*. Pancreatic schwannoma presenting as a cystic lesion. *Gastrointest Endosc* 2009;69:341.

[Downloaded free from http://www.eusjournal.com on Sunday, April 1, 2018, IP: 87.15.71.110]

2. Li S, Ai SZ, Owens C, *et al*. Intrapancreatic schwannoma diagnosed by endoscopic ultrasound-guided fine-needle aspiration cytology. *Diagn Cytopathol* 2009;37:132-5.
3. Barresi L, Tarantino I, Granata A, *et al*. Endoscopic ultrasound-guided fine-needle aspiration diagnosis of pancreatic schwannoma. *Dig Liver Dis* 2013;45:523.
4. Antonini F, Santinelli A, Macarri G. Endoscopic ultrasound-guided fine-needle aspiration of an unusual pancreatic mass. *Clin Gastroenterol Hepatol* 2015;13:e25.
5. Nishikawa T, Shimura K, Tsuyuguchi T, *et al*. Contrast-enhanced harmonic EUS of pancreatic schwannoma. *Gastrointest Endosc* 2016;83:463-4.