



Subcortical grey matter changes associated with motor symptoms evaluated by the Unified Parkinson's disease Rating Scale (part III): A longitudinal study in Parkinson's disease

Céline Charroud^{*}, Luca Turella

Center for Mind/Brain Sciences - CIMeC, University of Trento, Rovereto (TN), Italy

ARTICLE INFO

Keywords:

Basal Ganglia
Grey matter
Magnetic Resonance Imaging
Motor skills
Parkinson disease

ABSTRACT

Parkinson disease (PD) is characterized by motor deficits related to structural changes in the basal ganglia-thalamocortical circuits. However, it is still unclear the exact nature of the association between grey matter alterations and motor symptoms.

Therefore, the aim of our investigation was to identify the subcortical modifications associated with motor symptoms of PD over time - adopting voxel-based morphometry (VBM) and automated volumetry methods.

We selected fifty subjects with PD from the Parkinson's Progression Markers Initiative (PPMI) database, who performed an MRI session at two time points: at baseline (i.e. at maximum 2 years after clinical diagnosis of PD) and after 48 months. Motor symptoms were assessed using the part III of the Unified Parkinson's Disease Rating Scale at the two time points.

Our VBM and volumetric analyses showed a general atrophy in all subcortical regions when comparing baseline with 48 months. These findings confirmed previous observations indicating a subcortical alteration over time in PD. Furthermore, our findings supported the idea that a reduced volume in the thalamus and an increased volume in pallidum may be related to the decline in motor skills. These structural modifications are in accordance with the functional model of the basal ganglia-thalamocortical circuits controlling movements. Moreover, VBM and volumetry provided partially overlapping results, suggesting that these methods might capture complementary aspects of brain degeneration in PD.

1. Introduction

Parkinson disease (PD) is the second-most common neurodegenerative disease and it is mainly characterized by motor symptoms like tremor, bradykinesia, muscular rigidity and/or postural instability (Poewe et al., 2017; Papagno and Trojano, 2018; Trojano and Papagno, 2018). It is well known that parkinsonism would result in the loss of dopaminergic neurons in the substantia nigra leading to a functional and structural modification of the basal ganglia-thalamocortical circuits (DeLong and Wichmann, 2007; Marreiros et al., 2013; Galvan et al., 2015; Caligiore et al., 2016). However, very little is known about the subcortical structural modifications underlying PD and of their association with motor symptoms.

The majority of the studies on grey matter changes in PD focused on comparing PD patients with healthy controls. All these investigations showed that people living with PD have a general reduction in grey

matter volume bilaterally, comprising the following subcortical structures: amygdala (Rektorova et al., 2014; Li et al., 2017b), hippocampus (Summerfield et al., 2005; Pitcher et al., 2012; Rektorova et al., 2014), putamen (Lisanby et al., 1993; Ghaemi et al., 2002; O'Neill et al., 2002; Krabbe et al., 2005; Summerfield et al., 2005; Geng et al., 2006; Lee et al., 2011; Pitcher et al., 2012; Lewis et al., 2016), pallidum (O'Neill et al., 2002) caudate nucleus (Lisanby et al., 1993; Ej et al., 2004; Lee et al., 2011; Jia et al., 2015; Mak et al., 2015; Lewis et al., 2016; Cui et al., 2020; Fang et al., 2020) and nucleus accumbens (Summerfield et al., 2005; Mak et al., 2015). In contrast, the nature of the modifications in the thalamus still remains unclear, as some studies described a decrease in grey matter intensity/volume (Lisanby et al., 1993; Ej et al., 2004; Summerfield et al., 2005; Lee et al., 2011; Pitcher et al., 2012; Cui et al., 2020), whereas others showed an increase (Kassubek et al., 2002; Jia et al., 2015).

Other studies examined the progression of the disease by comparing

^{*} Corresponding author.

E-mail address: celine.charroud@hotmail.fr (C. Charroud).

<https://doi.org/10.1016/j.nicl.2021.102745>

Received 21 December 2020; Received in revised form 26 March 2021; Accepted 23 June 2021

Available online 29 June 2021

2213-1582/© 2021 The Authors.

Published by Elsevier Inc.

This is an open access article under the CC BY-NC-ND license

(<http://creativecommons.org/licenses/by-nc-nd/4.0/>).

patients at different stages of the disease (i.e. early vs. late disease stages) (Summerfield et al., 2005; Xia et al., 2013; Mak et al., 2015; Blair et al., 2019). They showed a grey matter atrophy in bilateral hippocampus during the more advanced stages of the disease. Another study also described a loss in grey matter volume in pallidum only in more advanced stages of PD (Geng et al., 2006).

All these findings suggest that structural changes in PD are progressive throughout the evolution of the disease and might affect differently each specific subcortical structure. In addition, these neuroimaging investigations described a general alteration of subcortical structures associated with PD, but it is difficult to link these structural modifications to specific symptoms of the disease.

Recent studies investigated the possible association between subcortical modifications with specific PD symptoms, by correlating grey matter intensity/volume with specific clinical or neuropsychological evaluations. In particular, several studies focused on motor symptoms and investigated the association between anatomical modifications and motor disabilities (assessed with the part III of unified Parkinson's disease rating scale, UPDRS-III). These investigations reported decreased grey matter volume associated with increasing motor severity in the bilateral caudate nucleus as well as in the bilateral putamen (Li et al., 2017a). Another research showed a similar association for the left caudate but not for the right one (Zarei et al., 2013). Finally, several studies reported no significant correlations with motor severity in subcortical structures such as the thalamus, caudate nucleus, putamen and pallidum (Jia et al., 2015; Lewis et al., 2016; Cui et al., 2020). It is important to consider that the heterogeneity of these results could be related to the stage of patients which are generally associated with different levels of motor symptom severity. Indeed, these studies considered patients at early (Li et al., 2017a), middle (Cui et al., 2020) or all (Zarei et al., 2013; Jia et al., 2015; Lewis et al., 2016) stages of the disease. To summarize, there is no clear consensus on the association between modifications in grey matter volume and motor symptoms in PD. Our study wanted to tackle this issue, which clearly required further investigation (Cui et al., 2020).

Surprisingly, a large part of the literature on this topic is based on studies adopting a cross-sectional approach, i.e. investigating PD patients at a specific time point of the disease. This approach might have limited the sensitivity to identify subtle structural changes induced by PD which might be hidden by large interindividual variability (Mills and Tamnes, 2014; Mak et al., 2015). In addition, this focus on cross-sectional studies could explain the discrepancies associated with structural modifications described above and the lack of consistency in the description of gradual structural changes associated with PD evolution. Longitudinal studies would improve the quantification at the individual level of these modifications, since the same group will be compared at different time points. Indeed, one longitudinal study showed that PD patients with mild cognitive impairment demonstrated a more extensive atrophy in bilateral hippocampus relative to PD without cognitive impairment after 18 months of follow-up (Mak et al., 2015). Another longitudinal research revealed a progressive decrease in gray matter volume in the bilateral caudate in PD when comparing a baseline measurement with 12-months follow-up data (Jia et al., 2015).

To sum up, the inconsistent findings associated with the subcortical brain modifications underlying PD make it difficult to gather a complete picture of the atrophic process happening in this neurodegenerative disease. Thus, it is crucial to determine the structural substrates linked to disease progression and their association with motor deficits, in the perspective to improve the diagnosis of PD and to identify novel and efficient targets for therapy. A surgical (e.g. deep brain stimulation) or medication (e.g. dopaminergic drugs) treatment can be more effective through a better determination of the target (Stoker et al., 2018).

Therefore, the first aim of the present research is to assess the subcortical changes associated with PD over time. We hypothesize that PD patients should show reduced grey matter volume in subcortical regions when comparing two consecutive time points (around the time

of the first clinical diagnosis of PD and after 48 months). In addition, the second objective of the study was to clarify the possible association between subcortical grey matter volumes and motor symptoms.

To this end, we adopted two classical methods to assess grey matter changes: voxel-based morphometry (VBM) and volumetry. At the moment, it is still not clear which is the best method to characterize structural brain modifications between VBM - generally preferred by most researcher - and volumetry. This lack of consensus has led several researchers to adopt both methods to investigate the same dataset (Emerton et al., 2009; Voormolen et al., 2010; Xia et al., 2013; Cui et al., 2020). Indeed, these approaches seem to provide complementary information about structural changes (Testa et al., 2004; Giuliani et al., 2005; Juh et al., 2006), as they detect differences of grey matter volume at the voxel (VBM) or at the ROI level (volumetry). So, it was suggested to use these methods in conjunction to capture complementary aspects of brain modification over time (Testa et al., 2004; Giuliani et al., 2005; Juh et al., 2006; Emerton et al., 2009). Therefore, in the present study, we compare the results from the VBM and ROI-based volumetry analysis to gather additional knowledge on this topic which is still largely debated.

2. Materials and methods

2.1. Population

The data were derived from the database of the on-going Parkinson's Progression Markers Initiative (PPMI), comprising a total of 4717 volunteers (age > 30 years) enrolled in different cohorts (healthy control, PD, de novo PD, PD without evidence of a dopaminergic deficit, prodromal, genetic cohort and genetic registry). This study aims to investigate the evolution of clinical, biologic and imaging markers in PD patients to improve clinical trials of disease-modifying therapies and expand knowledge of disease etiology (Parkinson Progression Marker Initiative, 2011; Marek et al., 2018). The project started in 2010 in multiple clinical sites (United States, Europe, Israel, and Australia). The PPMI provides a longitudinal follow-up of the database at least every year which is still in progress. All details are available online at ppmi-info.org.

The diagnosis of PD was assessed at maximum 2 years before baseline and the disease stage was evaluated as Hoehn and Yahr stage I or II. Patients must have an asymmetric resting tremor or asymmetric bradykinesia or two of resting tremor, bradykinesia and rigidity. A DaTscan was also performed to confirm the PD diagnosis by a screening of dopamine transporter measures. Patients were untreated within at least 6 months of enrollment and have no clinical diagnosis of dementia (Emre et al., 2007) or of atypical PD syndromes.

In our study, we focus on the PD cohort including patients that have performed an MRI at two time points. Since MRI data was available at baseline, after 12, 24 and 48 months, we decided to select the broadest period, i.e. baseline and 48 months of follow-up, to maximize the possibility of detecting differences in the evolution of the disease.

Fifty subjects with Parkinson Disease (PD) were selected from the PPMI database. The flow chart was illustrated in Fig. 1. From 4717 subjects on PPMI database, 796 were enrolled in the PD cohort and 404 carried out a MRI scan. Structural images acquired with the same MRI sequence were available for 60 subjects at the two selected time points, i.e. baseline and 48 months. All imaging data have been checked visually and we removed 10 subjects due to evident artifacts on the images.

In addition, motor symptoms were assessed using the part III of Unified Parkinson's Disease Rating Scale (UPDRS-III) also at baseline and 48 months of follow up. This score was available for the 50 PD patients at the two time points.

The Hoehn and Yahr Stage, the Geriatric Depression Score (GDS) and UPDRS-III scores were compared between baseline and 48 months using a paired samples Wilcoxon test.

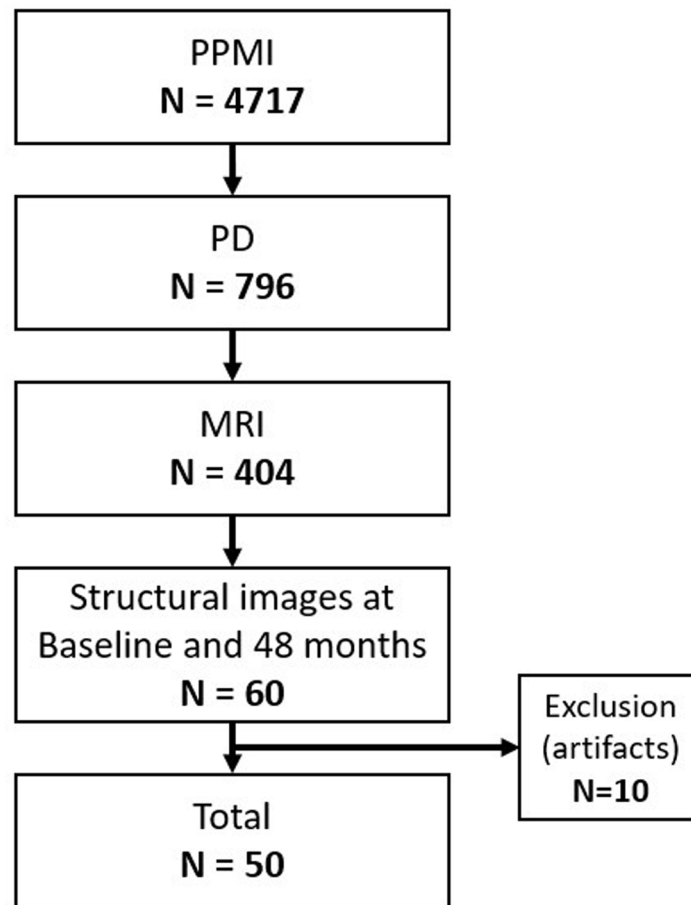


Fig. 1. Flow chart of the selection of subjects. Abbreviations: MRI = Magnetic Resonance Imaging, N = Number of subjects, PD = Parkinson Disease, PPMI = Parkinson's Progression Markers Initiative.

2.2. MRI data acquisition

Neuroimaging data were collected using a 3 T scanner (TrioTim, Siemens, Germany) with a 32-channel head coil. For each MRI session, structural images (3DT1-MPRAGE) were acquired according to the following parameters: TR/TE/TI = 2300/3.0/900 ms, flip angle = 9°, voxel size = 1x1x1 mm, 176 slices.

2.3. MRI data pre-processing

Pre-processing of the MRI images was carried out using the CAT12 toolbox (<http://www.neuro.uni-jena.de/cat/>) within SPM12 (Wellcome Department of Imaging Neuroscience Group, London, UK; <http://www.fil.ion.ucl.ac.uk/spm>) in MATLAB software (The Mathworks Inc.; MA, USA, R2019b).

After a correction of bias field inhomogeneity, the anatomical images at both time-points were segmented into grey matter, white matter, and cerebrospinal fluid (Ashburner and Friston, 2005). The sum of these three components were used to assess the total intracranial volume in the native space. Then, grey matter images were normalized into the standard Montreal Neurological Institute (MNI) space using the Diffeomorphic Anatomic Registration Through Exponentiated Lie algebra algorithm (DARTEL) (Ashburner 2007). During this step, the nonlinear deformations matrices (forward and inverse) were produced by a high-dimensional spatial registration to transform the images in the individual subject on to MNI space (forward) and in MNI space on to the individual subject (inverse). Finally, smoothing was applied on normalized images with a Gaussian kernel of a full width at half maximum (FWHM) of 8 mm. The segmented images were visually

inspected and a quality check was performed by estimating the weighted image quality rating.

Finally, a total of fourteen regions of interest (ROI) were selected. We selected seven ROI in each hemisphere: the nucleus accumbens, amygdala, caudate, hippocampus, pallidum, putamen and thalamus. ROI masks were generated from the "neuromorphometric" atlas (MNI space) introduced in SPM12. All ROIs were checked visually in all participants to assure the quality of the mask.

2.4. MRI statistical analyses

2.4.1. VBM

A voxel-wise general linear model (GLM) group analyses were performed on normalized grey matter images using permutation-based non-parametric testing (5,000 permutations) adopting the Randomize toolbox implemented in FSL (<https://fsl.fmrib.ox.ac.uk/fsl/fslwiki/Randomise>). We aimed at assessing: (i) local grey matter differences between baseline and 48 months with a paired *t*-test and (ii) local grey matter modifications associated with UPDRS-III scores evaluated at baseline then at 48 months adopting an ANalysis of COVariance (ANCOVA) analyses. Furthermore, we identified the changes in UPDRS III over time by assessing the difference in UPDRS III between 48 months and baseline as well as the difference in grey matter volume between 48 months and baseline. All analyses were performed separately for each ROI which was introduced as a mask.

All analyses included three corrections: Family-Wise Error rate (FWE), Threshold-Free Cluster Enhancement (TFCE) and cluster size correction. The FWE method was applied at the voxel level with a statistical *p*-value threshold corresponding to $p < 0.05$ to prevent the

reporting of false positives whereas the TFCE was performed at the cluster level to correct for multiple comparisons using 5000 permutations. TFCE correction is a standard approach which is effective to deal with smoothness non-stationary in VBM analyses and its effects on cluster-based inference (Salimi-Khorshidi et al., 2011; Finkelmeyer et al., 2017). We also adopted an arbitrary cluster correction inspired by SPM small volume correction in order to be more conservative; so only significant clusters with a minimum size of 40 voxels were reported. Furthermore, all results were age- and sex-adjusted using two covariates of no interest in the general linear model (GLM). The total intracranial volume was also included as third covariate to correct different brain sizes which is strongly recommended for all VBM analysis (Mechelli et al., 2005). Finally, cognitive status was added as a fourth covariate. We adopted the MoCA (Montreal Cognitive Assessment) to stratify our cohort. The MoCA score is representative of deficits in multiple cognitive domains like attention, executive functions, visuospatial capabilities and memory. We classified our participants as PD-normal (MoCA > 27), PD-mild cognitive impairment ($26 \leq \text{MoCA} \leq 23$) or PD-dementia ($\text{MoCA} \leq 22$) as suggested in previous studies (Hoops et al., 2009; Dalrymple-Alford et al., 2010; Jones et al., 2018). We modelled these three groups (PD-normal, PD-mild cognitive impairment, PD-dementia) in our fourth covariate.

2.4.2. Volumetry

Grey matter volume assessment was performed in each ROI using the standard CAT12 pipeline. Volumes were evaluated in their native space before any spatial normalization using the probabilistic atlas (“neuro-morphometric” atlas) implemented in CAT12. Then, all volumes were extracted in each ROI at both time-points.

Statistical analyses were performed using R software (version 3.6.3) in each ROI. Skewed variables (subcortical grey matter volumes) were log-transformed to normalize their distribution before statistical analyses (Nakama et al., 2011; Deverdun et al., 2016; Gerrits et al., 2016; Ritchie et al., 2017). A paired *t*-test was performed to examine the grey matter volume differences between baseline and 48 months of follow-up (adopting Bonferroni correction for multiple comparisons). Then, correlation analyses (Pearson’s correlation coefficient) were conducted to investigate the association between UPDRS-III scores and grey matter volume measures at each time separately (baseline and 48 months). Finally, correlation analyses based on the changes in UPDRS III and grey matter volume over time were also performed by assessing the difference in UPDRS III and the difference in grey matter volume in each ROI between two time points.

3. Results

3.1. Participant characteristics

The population of interest consisted in 50 PD patients (33 women and 17 men) with a mean age (standard deviation) of 59.8 (9.9) at baseline and 63.9 (9.9) at 48 months of follow-up. As expected, the Hoehn and Yahr Stage and UPDRS-III scores were significantly increased (H&Y: $p = 0.001$; UPDRSIII: $p = 0.0004$) between baseline and 48 months. Furthermore, the cognitive status was significantly different between baseline and 48 months ($p = 0.04$), so we added this variable as a covariate in our model. At baseline, 38 subjects were diagnosed as PD-normal and 12 subjects as PD-mild cognitive impairment. At 48 months, 32 subjects were classified as PD-normal, 15 subjects as PD-mild cognitive impairment and 3 subjects as PD-dementia.

It is important to note that the severity of the depression can influence motor performances and lead to subcortical structural changes especially at the onset of the disease (Prange et al., 2019). In our study, the Geriatric Depression Scale scores were not significantly different between baseline and 48 months ($p = 0.6$), therefore we decided not to include this variable as a covariate in our analyses.

The start of medication was very heterogeneous within our cohort of

patients (mean in months \pm SD: 9.8 ± 2.5), with a range of 0 (i.e. baseline) to 84 months (after the baseline).

Characteristics of the participants are detailed in Table 1.

3.2. VBM

Compared to baseline, PD subjects at 48 months showed a significant decrease in grey matter volume in all ROIs (nucleus accumbens, amygdala, caudate, hippocampus, pallidum, putamen and thalamus). No significant differences (i.e. increase in volume) were observed when baseline was compared to 48 months. Results are illustrated in Fig. 2 and Table 2.

At 48 months, grey matter volume was associated negatively with UPDRS-III scores in the bilateral thalamus and positively in the bilateral pallidum. Two significant clusters were found in the left thalamus. At baseline, no significant association was identified. These findings were reported in Fig. 3 and Table 3. Finally, no significant results were found when considering the changes over time (differences in UPDRS III and grey matter volume between 48 months and baseline).

3.3. Volumetry

Compared to baseline, PD subjects at 48 months showed significantly decreased grey matter volume in accumbens (left: $<10^{-3}$; right: 0.002), amygdala (left: $<10^{-3}$; right: $<10^{-3}$), caudate (left: $<10^{-3}$; right: $<10^{-3}$), hippocampus (left: $<10^{-3}$; right: $<10^{-3}$) and thalamus (left: $<10^{-3}$; right: $<10^{-3}$). These results were summarized in Table 4.

At baseline, grey matter volume was associated positively with UPDRS-III scores in the right pallidum ($r = 0.19$, $p = 0.02$). At 48 months, grey matter volume was associated negatively with UPDRS-III scores in the bilateral thalamus (left: $r = -0.30$, $p = 0.03$; right: $r = -0.35$, $p = 0.01$) and positively in the bilateral pallidum (left: $r = 0.39$, $p = 0.004$; right: $r = 0.35$, $p = 0.01$). These correlations are presented in Fig. 4 and Table 5. In addition, the grey matter volume change was significantly correlated with UPDRS III change in left pallidum ($r = -0.29$, $p = 0.04$) and left thalamus ($r = 0.28$, $p = 0.04$).

4. Discussion

The present study aimed to explore: (i) the anatomical changes in subcortical structures associated with PD over time and (ii) their associations with motor symptoms. To this aim, we adopted two approaches, i.e. VBM and volumetry.

Our results converged in identifying a general atrophy within subcortical structures associated with PD evolution. Both methods revealed a decrease either in grey matter intensity or volume over time in almost all subcortical regions when comparing baseline and 48 months, supporting the accepted subcortical alteration associated with PD progression (Summerfield et al., 2005; Pitcher et al., 2012; Mak et al., 2015; Cui et al., 2020). However, there were differences between these two methods, as volumetry showed no significant difference in the bilateral putamen and bilateral pallidum, unlike VBM. This result suggests that these two methods might provide partially dissociable, but complementary, descriptions of grey matter modifications.

Table 1

Characteristics of the participants. Data are mean (SD) or number of subjects (N). Abbreviations: GDS = Geriatric Depression Scale, UPDRS III = Unified Parkinson’s Disease Rating Scale, part III.

PD patients	Baseline	48 months
N (men/women)	50 (33/17)	50 (33/17)
Age (mean \pm SD)	59.8 \pm 9.9	63.9 \pm 9.9
Hoehn and Yahr Stage score (mean \pm SD)	1.5 \pm 0.5	1.9 \pm 0.5
Disease duration (months \pm SD)	5.9 \pm 5.9	55.3 \pm 6.2
GDS (mean \pm SD)	5.1 \pm 1.6	5.2 \pm 1.5
UPDRS III (mean \pm SD)	19.9 \pm 9.5	25.8 \pm 12.3

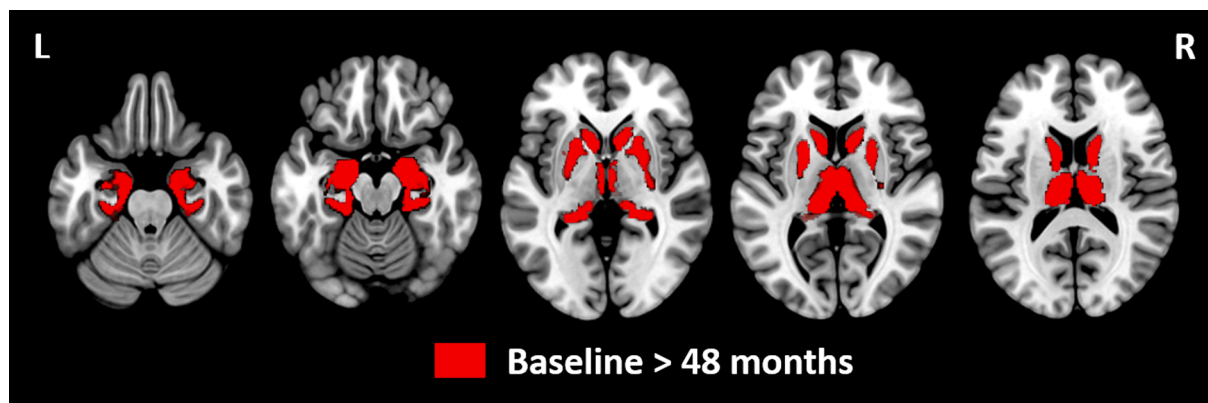


Fig. 2. Statistical parametric maps showing differences between baseline and 48 months of follow-up using voxel-based morphometry analyses. Grey matter volume was decreased in all subcortical regions (nucleus accumbens, amygdala, caudate, hippocampus, pallidum, putamen and thalamus) at 48 months relative to baseline. No significant differences were identified at baseline relative to 48 months. Results were reported using threshold-free cluster enhancement and $p < 0.05$ family-wise error rate error corrected with a cluster size > 40 voxels. Age, gender, total intracranial volume and cognitive status were also considered as covariates in the model. Regions are displayed on transverse slices (MNI space, MRIcroGL software, MNI152 template). Abbreviations: L = Left, R = Right.

Table 2

Subcortical grey matter regions showing differences between baseline and 48 months of follow-up using voxel-based morphometry analyses. Local maxima were reported, including cluster size and anatomical region. Findings were reported in the Montreal Neurological Institute space (x, y, and z). Results were reported using threshold-free cluster enhancement and $p < 0.05$ family-wise error rate error corrected with a cluster size > 40 voxels. Age, gender, total intracranial volume and cognitive status were also considered as covariates in the model. Abbreviations: L = Left, R = Right, ROI = Region Of Interest.

Cluster	Voxels size	t value	MNI coordinates		
			x	y	z
L Accumbens	61	59.5	-10.5	6	-13.5
R Accumbens	45	53.7	12	7.5	-9
L Amygdala	131	62.7	-15	-6	-22.5
R Amygdala	117	65.3	24	-4.5	-24
L Caudate	708	63.2	-10.5	9	-6
R Caudate	787	69.7	9	9	-4.5
L Pallidum	206	47.7	-22.5	-10.5	-7.5
R Pallidum	227	60.6	25.5	-9	-7.5
L Hippocampus	664	71.4	-18	-15	-21
R Hippocampus	840	73.3	27	-10.5	-24
L Putamen	560	59.5	-13.5	6	-13.5
R Putamen	549	61.1	15	7.5	-13.5
L Thalamus	1105	67.6	-3	-9	-4.5
R Thalamus	1050	67.5	19.5	-31.5	-4.5

Regarding the association between grey matter volume and UPDRS-III scores, our findings support the idea that a reduced volume in the thalamus and an increased volume in pallidum may be related to the general decline in motor skills assessed with this scale. VBM and volumetry approaches revealed a negative correlation in the bilateral thalamus and a positive correlation in the bilateral pallidum at 48 months. A positive correlation was also identified using volumetry method in the right pallidum at baseline. Furthermore, the changes in UPDRS-III over time were correlated with the changes in grey matter volume over time positively in left thalamus and negatively in left pallidum enhancing these assumptions.

4.1. Decreased grey matter volume between baseline and 48 months

Previous MRI studies comparing PD patients to healthy control showed a loss of grey matter volume in subcortical regions using VBM or volumetry approach. Several studies reported a bilateral decrease in thalamus (VBM: Ej et al., 2004; Summerfield et al., 2005; Cui et al., 2020; volumetry: Lee et al., 2011; Pitcher et al., 2012), amygdala (VBM: Li et al., 2017b), hippocampus (VBM: Summerfield et al., 2005;

volumetry: Pitcher et al., 2012), putamen (VBM: Summerfield et al., 2005; volumetry: Ghaemi et al., 2002; O'Neill et al., 2002; Krabbe et al., 2005; Geng et al., 2006; Lee et al., 2011; Pitcher et al., 2012; Lewis et al., 2016), nucleus accumbens (VBM: Summerfield et al., 2005; volumetry: Mak et al., 2015), pallidum (volumetry: O'Neill et al., 2002) and caudate nucleus (VBM: Ej et al., 2004; Cui et al., 2020; volumetry: Lee et al., 2011; Mak et al., 2015; Lewis et al., 2016; Fang et al., 2020). In addition, other studies demonstrated a reduction in the bilateral hippocampus (VBM: Summerfield et al., 2005; Xia et al., 2013; Blair et al., 2019; volumetry: Mak et al., 2015) and pallidum (volumetry: Geng et al., 2006) as a function of the different stages of the disease. In our study, we confirmed these observations showing a decrease in almost all subcortical region at 48 months compared to baseline (clinical diagnosis of PD) using both VBM and volumetry method. Therefore, our findings may represent a specific alteration of the subcortical structures over time characterizing Parkinson disease progression.

4.2. Association with UPDRS-III score

We observed bilaterally that smaller thalamus volumes were correlated with higher UPDRS-III scores (more severe motor symptoms) at 48 months. Thalamus has been generally neglected in the literature on subcortical modifications associated with PD (Lewis et al., 2016; Cui et al., 2020). Only one study involving data of the PPMI database reported no correlation between the thalamic volume and UPDRS-III scores both at baseline and at 12 months follow-up using VBM approach (Jia et al., 2015). Similarly, our results did not show a significant correlation at baseline, but showed an effect at 48 months using both VBM and volumetry method. A positive significant correlation was also identified on the changes over time in left thalamus. This suggests that thalamic changes could have a slow progression and occur only at the late stage of the disease. These structural modifications are in accordance with the functional model of basal ganglia-thalamocortical circuits controlling movements (Albin et al., 1989; DeLong and Wichmann, 2007; Rubin et al., 2012; Marreiros et al., 2013; Galvan et al., 2015; Caligiore et al., 2016; McGregor and Nelson, 2019). This model proposes that the dopaminergic loss drives abnormal activity in the basal ganglia, which in turns lead to an excess inhibition of the thalamocortical pathway. It is thus expected that the decline in thalamic activity is associated with motor deficits of PD, especially as the thalamus (ventral anterior and ventrolateral nuclei) is known to project towards motor cortical regions (Galvan et al., 2015). Therefore, our results might reflect a structural modification following thalamic functional changes, as we observed a decreased volume in thalamus associated with increased motor impairment only at 48 months.

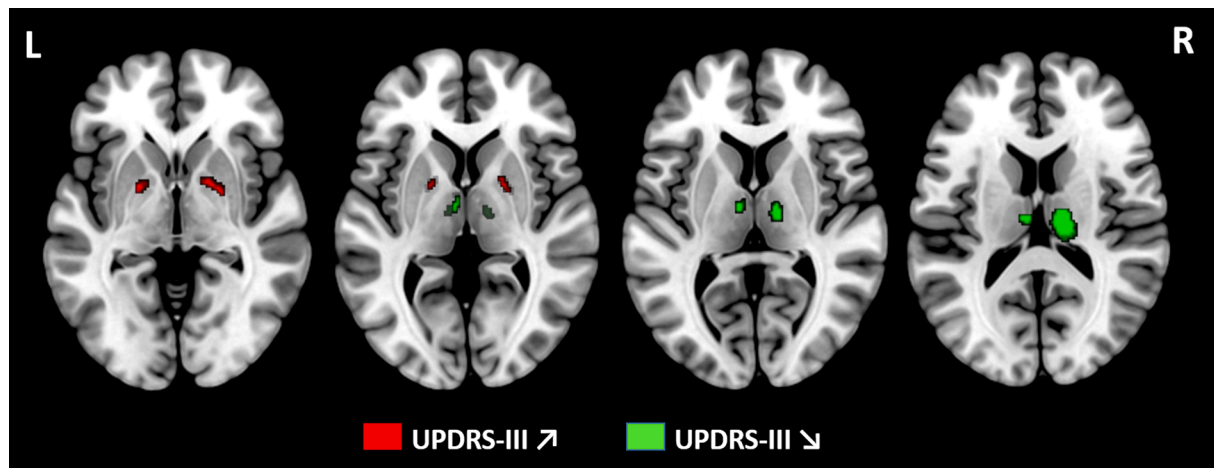


Fig. 3. Statistical parametric maps showing negative correlation between grey matter volume and UPDRS-III scores at 48 months using voxel-based morphometry analyses. Results showed a positive association between grey matter volume and UPDRS-III in bilateral pallidum at 48 months. Conversely, a negative association was identified in bilateral thalamus at 48 months. No findings were significant at baseline. Results were reported using threshold-free cluster enhancement and $p < 0.05$ family-wise error rate error corrected with a cluster size > 40 voxels. Age, gender, total intracranial volume and cognitive status were also considered as covariates in the model. Regions are displayed on transverse slices (MNI space, MRIcroGL software, MNI152 template). Abbreviations: L = Left, R = Right.

Table 3

Subcortical grey matter regions showing correlation between grey matter volume and UPDRS-III scores at 48 months using voxel-based morphometry analyses. Local maxima were reported, including cluster size and anatomical region. Findings were reported in the Montreal Neurological Institute space (x, y, and z). Results were reported using threshold-free cluster enhancement and $p < 0.05$ family-wise error rate error corrected with a cluster size > 40 voxels. Age, sex, total intracranial volume and cognitive status were also considered as covariates in the model. Abbreviations: L = Left, R = Right, ROI = Region of Interest, UPDRS-III = Unified Parkinson's Disease Rating Scale, part III.

Cluster	Voxels size	t value	MNI coordinates		
			x	y	z
UPDRS-III decreased					
L Thalamus	933	1.8	-6	-9	1.5
L Thalamus	56	1.8	-21	-30	-1.5
R Thalamus	1174	1.9	13.5	-18	15
UPDRS-III increased					
L Pallidum	40	1.9	19.5	0	0
R Pallidum	69	2.0	22.5	-1.5	1.5

Table 4

Subcortical grey matter regions showing differences between baseline and 48 months using volume assessment analyses. The comparison between baseline and 48 months was assessed using a paired-t-test, Bonferonni corrected. The asterisk indicates significant differences at $p < 0.05$. Abbreviations: L = Left, R = Right, ROI = Region of Interest.

ROIs	Volume at Baseline	Volume at 48 months	P value
L Accumbens	405.0 ± 57.3	390.6 ± 58.9	$<10^{-3} *$
R Accumbens	410.3 ± 59.9	397.4 ± 60.5	0.002*
L Amygdala	964.1 ± 106.6	938.1 ± 104.4	$<10^{-3} *$
R Amygdala	953.7 ± 101.0	921.3 ± 120.6	$<10^{-3} *$
L Caudate	2624.7 ± 376.5	2522.0 ± 392.8	$<10^{-3} *$
R Caudate	2770.2 ± 349.4	2685.9 ± 353.7	$<10^{-3} *$
L Hippocampus	3144.6 ± 291.7	3063.0 ± 310.2	$<10^{-3} *$
R Hippocampus	3503.9 ± 338.6	3404.4 ± 364.5	$<10^{-3} *$
L Thalamus	4920.8 ± 520.6	4736.0 ± 565.6	$<10^{-3} *$
R Thalamus	5208.3 ± 504.1	5088.8 ± 583.9	$<10^{-3} *$
L Pallidum	171.1 ± 80.5	181.9 ± 89.9	0.94
R Pallidum	193.1 ± 99.1	202.0 ± 105.3	0.82
L Putamen	3584.6 ± 547.7	3546.7 ± 551.4	0.12
R Putamen	3501.1 ± 419.1	3460.2 ± 411.2	0.12

The same functional model of basal ganglia-thalamocortical circuits support the idea that a dysfunction of the pallidum would be responsible of the inhibition of the thalamo-cortical pathway in PD (Albin et al., 1989; DeLong and Wichmann, 2007; Rubin et al., 2012; Marreiros et al., 2013; Galvan et al., 2015; Caligiore et al., 2016; McGregor and Nelson, 2019). The model proposes that the selective depletion of dopaminergic neurons of the substantia nigra will induce an overactivation in the pallidum, triggering the inhibition of the thalamo-cortical pathway. Therefore, the dopaminergic loss would lead to abnormal excitability in pallidum which also should contribute to motor impairment. In our study, we showed a positive correlation between the grey matter volume in pallidum and UPDRS-III scores, as well as a negative correlation between the UPDRS III/grey matter volume changes over time in the left pallidum. These findings suggest that a large volume in pallidum could be related to increased severity of motor symptoms. Considering the general atrophy of all subcortical structures in PD over time, a possible interpretation of our data might be that the atrophy in the pallidum might be a possible compensatory mechanism as it correlates with less motor impairment.

4.3. VBM and volumetry approach

Our VBM and volumetry analyses showed only partially overlapping results. Previous studies have provided mixed results in this respect. Several investigations showed only a limited convergence between these two methods (Tisserand et al., 2002; Giuliani et al., 2005; Emerton et al., 2009; Voormolen et al., 2010; Cui et al., 2020), whereas others showed a total (Good et al., 2001; Job et al., 2003; Luders et al., 2004) or no convergence at all (Juh et al., 2006). This variability could be explained by differences in the type of measurements: VBM detects qualitatively the local density changes in brain tissue, while volumetry can provide quantitatively measure of brain volume (Tisserand et al., 2002). Therefore, volumetry would be less sensitive than VBM to identify subtle deficits, as local modifications in a specific part of the selected region might be diluted and disappear when selecting a too large ROI (Tisserand et al., 2002; Voormolen et al., 2010). The relevant information about structural modification could thus be hidden by the other unaltered parts of the ROI. As mentioned earlier, we found only partially overlapping results using VBM during the comparison between the two time points, whereas volumetry approach was more sensitive to identify association between grey matter modifications and motor symptoms. These results support the idea that the choice of the type of method is

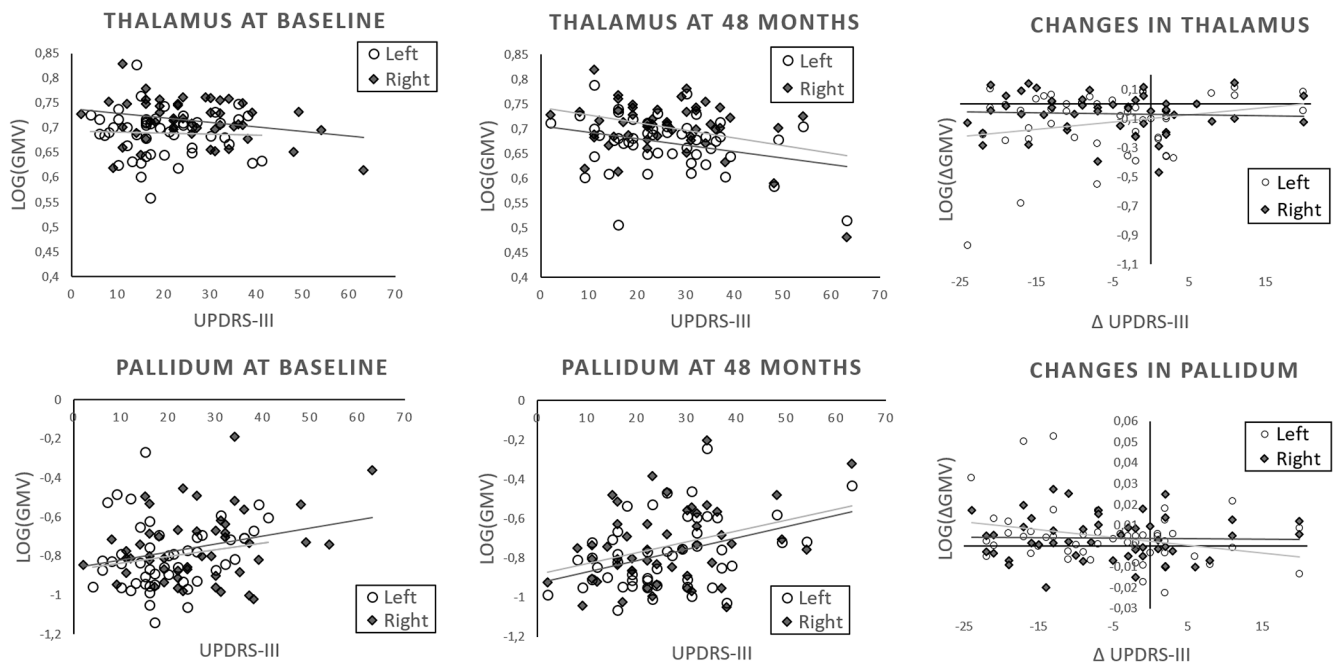


Fig. 4. Correlation between grey matter volume and UPDRS-III scores at baseline, 48 months and over time. At baseline, one positive correlation was identified between grey matter volume and UPDRS-III scores in the right pallidum. A non-significant correlation was observed in the bilateral thalamus and left pallidum. At 48 months, a positive correlation was found between grey matter volume and UPDRS-III scores in bilateral pallidum whereas a negative correlation was identified in bilateral thalamus. Changes between 48 months and baseline in grey matter volume and UPDRS-III were correlated positively in left thalamus and negatively in left pallidum. Pearson correlations were reported with a statistical threshold of $p < 0.05$. Data (grey matter volume) were log-transformed to normalize the distribution. Abbreviations: UPDRS = Unified Parkinson's Disease Rating Scale.

Table 5

Subcortical grey matter regions showing correlation between grey matter volume and UPDRS-III scores at baseline, 48 months and over time using volume assessment analyses. Pearson correlations (r) are reported with a significant statistical threshold of $p < 0.05$ reported by an asterisk (*). Abbreviations: BL = BaseLine, L = Left, R = Right, ROI = Region Of Interest.

ROIs	Pearson r	P value
Baseline		
L Pallidum	0.19	0.17
R Pallidum	0.32	0.02*
L Thalamus	-0.045	0.75
R Thalamus	-0.12	0.42
48 months		
L Pallidum	0.39	0.004*
R Pallidum	0.35	0.01*
L Thalamus	-0.30	0.03*
R Thalamus	-0.35	0.01*
Difference (48-BL)		
L Pallidum	-0.29	0.04*
R Pallidum	-0.027	0.85
L Thalamus	0.28	0.04*
R Thalamus	-0.050	0.73

crucial: a qualitative method should be preferred for comparative data (t -test), whereas a quantitative method should be selected in the analysis of associations with neuropsychological data (regression/correlation). Therefore, we confirm that these methods should be used jointly as complementary tools, as already suggested previously (Testa et al., 2004; Giuliani et al., 2005; Juh et al., 2006; Emerton et al., 2009; Voormolen et al., 2010; Cui et al., 2020).

4.4. Limitations of our study

We acknowledged that our study did not provide novel evidence regarding the caudate nucleus. As reported in the Introduction, the

investigation of the association between grey matter volume in the caudate nucleus and motor impairment is still not clear. Several studies reported no correlation with the UPDRS-III scores (Jia et al., 2015; Lewis et al., 2016; Cui et al., 2020), or a negative correlation bilaterally in the caudate nucleus (Li et al., 2017a) or only in the left caudate nucleus (Zarei et al., 2013). In our study, results were not statistically significant using both VBM and volumetry methods, confirming the difficulties in establishing this possible relationship. An explanation to this lack of effect could be the selection of too large ROI, encompassing different subregions, which might not be optimal to identify subtle structural modifications (Tisserand et al., 2002; Voormolen et al., 2010).

Following this line of thinking, it could be also interesting to investigate the role of the different nuclei of the thalamus, as the ventral anterior and the ventrolateral nuclei, which have been also related to motor impairments according to the model of the thalamo-cortical functional loops (Albin et al., 1989; Rubin et al., 2012; Galvan et al., 2015; Caligiore et al., 2016; McGregor and Nelson, 2019). Consequently, additional work should be performed to better define the different subdivisions in each anatomical ROI – and possibly adopting high-resolution sub-millimeter anatomical images – in order to better understand parkinsonism-related changes and their association with the motor deficits.

5. Conclusion

To conclude, our study confirmed the existence of a general atrophic process within subcortical structures following the progression Parkinson's disease, described as a decreased grey matter volume in all subcortical regions over time (48 months) using both VBM and volumetry approach. We highlighted for the first time that a decreased grey matter volume in thalamus and an increased grey matter volume in pallidum were correlated with increased motor symptoms severity. These structural changes are consistent with the proposed role of basal ganglia-thalamocortical circuits in controlling movement in Parkinson's disease. Our results also broadened knowledge about the importance to

use VBM and volumetry as complementary approaches to investigate brain modifications in PD. All in all, our finding helped in better clarifying parkinsonism-related changes and their association with motor deficits, highlighting the thalamus and pallidum as possible targets to appropriate therapeutic intervention.

CRedit authorship contribution statement

Céline Charroud: Conceptualization, Investigation, Methodology, Software, Visualization. **Luca Turella:** Conceptualization, Investigation, Methodology, Software, Visualization.

Declaration of Competing Interest

The authors declare that they have no known competing financial interests or personal relationships that could have appeared to influence the work reported in this paper.

Acknowledgements

The study was supported by Comune di Rovereto, with the project: “Study of the neural bases underlying the beneficial effects of physical activity Parkinson’s disease”. Data used in the preparation of this article were obtained from the Parkinson’s Progression Markers Initiative (PPMI) database (www.ppmi-info.org/data). For up-to-date information on the study, visit www.ppmi-info.org. PPMI is sponsored and partially funded by the Michael J Fox Foundation for Parkinson’s Research and funding partners, including Abbvie, Allergan, Amathus therapeutics, Avid Radiopharmaceuticals, Biogen, BioLegend, Britsol-Myers Squibb, Celegene, Denali, GE Healthcare, Genetech, GlaxoSmithKline, Golub Capital, Handl Therapeutics, Insiteo, Janssen Neuroscience, Lilly, Lundbeck, Merck, Meso Scale Discovery, Neurocrine, Pfizer, Piramal, Prevail Therapeutics, Roche, Sanofi Genzyme, Servier, Takeda, Teva, UCB, verily and Voyager Therapeutics. Neither the funding agency nor any of the sponsors of the PPMI were involved in the design and conduct of the study; collection, management, analysis, and interpretation of the data; preparation, review, or approval of the manuscript; and decision to submit the manuscript for publication.

References

- Albin, R.L., Young, A.B., Penney, J.B., 1989. The functional anatomy of basal ganglia disorders. *Trends Neurosci.* 12 (10), 366–375. [https://doi.org/10.1016/0166-2236\(89\)90074-x](https://doi.org/10.1016/0166-2236(89)90074-x).
- Ashburner, J., 2007. A fast diffeomorphic image registration algorithm. *NeuroImage* 38 (1), 95–113. <https://doi.org/10.1016/j.neuroimage.2007.07.007>.
- Ashburner, J., Friston, K.J., 2005. Unified segmentation. *NeuroImage* 26 (3), 839–851. <https://doi.org/10.1016/j.neuroimage.2005.02.018>.
- Blair, J.C., Barrett, M.J., Patrie, J., Flanigan, J.L., Sperling, S.A., Jeffrey Elias, W., Jason Druzgal, T., 2019. Brain MRI reveals ascending atrophy in Parkinson’s disease across severity. *Front. Neurol.* 10 <https://doi.org/10.3389/fneur.2019.01329>.
- Caligiore, D., Helmich, R.C., Hallett, M., Moustafa, A.A., Timmermann, L., Toni, I., Baldassarre, G., 2016. Parkinson’s disease as a system-level disorder. *NPJ Parkinson’s Disease* 2 (1), 1–9. <https://doi.org/10.1038/npjparkd.2016.25>.
- Cui, X., Li, L., Lei, Y.u., Xing, H., Chang, H., Zhao, L.i., Qian, J., Song, Q., Zhou, S., Dong, C., 2020. Gray matter atrophy in Parkinson’s disease and the parkinsonian variant of multiple system atrophy: a combined ROI- and voxel-based morphometric study. *Clinics* 75. <https://doi.org/10.6061/clinics/2020/e1505>.
- Dalrymple-Alford, J.C., MacAskill, M.R., Nakas, C.T., Livingston, L., Graham, C., Crucian, G.P., Melzer, T.R., Kirwan, J., Keenan, R., Wells, S., Porter, R.J., Watts, R., Anderson, T.J., 2010. The MoCA: well-suited screen for cognitive impairment in Parkinson disease. *Neurology* 75 (19), 1717–1725. <https://doi.org/10.1212/WNL.0b013e3181fc29c9>.
- DeLong, M.R., Wichmann, T., 2007. Circuits and circuit disorders of the basal ganglia. *Arch. Neurol.* 64 (1), 20–24. <https://doi.org/10.1001/archneur.64.1.20>.
- Deverdun, J., Akbaraly, T.N., Charroud, C., Abdennour, M., Brickman, A.M., Chemouny, S., Steffener, J., Portet, F., Bonafe, A., Stern, Y., Ritchie, K., Molino, F., Le Bars, E., Menjot de Champfleury, N., 2016. Mean arterial pressure change associated with cerebral blood flow in healthy older adults. *Neurobiol. Aging* 46, 49–57. <https://doi.org/10.1016/j.neurobiolaging.2016.05.012>.
- Ej, Burton, McKeith Ig, Burn Dj, Williams Ed, et O’Brien Jt. 2004. Cerebral Atrophy in Parkinson’s Disease with and without Dementia: A Comparison with Alzheimer’s Disease, Dementia with Lewy Bodies and Controls. *Brain : A J. Neurol.* 127 (4). <https://doi.org/10.1093/brain/awh088>.
- Emerton, B.C., Jerram, M., Deckersbach, T., Dougherty, D.D., Fulwiler, C., Gansler, D.A., 2009. A Comparison of Voxel-based morphometry and volumetry methods in the context of the neural basis of aggression. *Brain Imaging Behav.* 3 (4), 332–341. <https://doi.org/10.1007/s11682-009-9075-2>.
- Emre, Murat, Dag Aarsland, Richard Brown, David J. Burn, Charles Duyckaerts, Yoshikino Mizuno, Gerald Anthony Broe, et al. 2007. Clinical diagnostic criteria for dementia associated with Parkinson’s disease. *Movement Disorders: Official Journal of the Movement Disorder Society* 22 (12): 1689-1707; quiz 1837. <https://doi.org/10.1002/mds.21507>.
- Fang, E., Ann, C.N., Maréchal, B., Lim, J.X., Tan, S.Y.Z., Li, H., Gan, J., Tan, E.K., Chan, L., 2020. Differentiating Parkinson’s disease motor subtypes using automated volume-based morphometry incorporating white matter and deep gray nuclear lesion load. *J. Magn. Reson. Imaging* 51 (3), 748–756. <https://doi.org/10.1002/jmri.26887>.
- Finkelmeyer, A., He, J., Maclachlan, L., Watson, S., Gallagher, P., Newton, J.L., Blamire, A.M., 2017. Grey and white matter differences in Chronic Fatigue Syndrome – A voxel-based morphometry study. *NeuroImage: Clinical* 17 (Supplement C), 24–30. <https://doi.org/10.1016/j.nicl.2017.09.024>.
- Galvan, Adriana, Annaelle Devergnas, et Thomas Wichmann. 2015. Alterations in neuronal activity in basal ganglia-thalamocortical circuits in the parkinsonian state. *Front. Neuroanatomy* 9 (février). <https://doi.org/10.3389/fnana.2015.00005>.
- Geng, Dao-Ying, Yu-Xin Li, et Chi-Shing Zee. 2006. Magnetic Resonance Imaging-Based Volumetric Analysis of Basal Ganglia Nuclei and Substantia Nigra in Patients with Parkinson’s Disease. *Neurosurgery* 58 (2): 256-62; discussion 256-262. <https://doi.org/10.1227/01.NEU.0000194845.19462.7B>.
- Gerrits, Niels J.H.M., Anita C. van Loenhoud, Stan F. van den Berg, Henk W. Berendse, Elisabeth M.J. Foncke, Martin Klein, Diederick Stoffers, Ysbrand D. van der Werf, et Odile A. van den Heuvel. 2016. Cortical thickness, surface area and subcortical volume differentially contribute to cognitive heterogeneity in Parkinson’s Disease. *PLoS One* 11 (2). <https://doi.org/10.1371/journal.pone.0148852>.
- Ghaemi, M., Hilker, R., Rudolf, J., Sobesky, J., Heiss, W., 2002. Differentiating multiple system atrophy from Parkinson’s disease: contribution of striatal and midbrain MRI volumetry and multi-tracer PET imaging. *J. Neurol. Neurosurg. Psychiatry* 73 (5), 517–523. <https://doi.org/10.1136/jnnp.73.5.517>.
- Giuliani, N.R., Calhoun, V.D., Pearlson, G.D., Francis, A., Buchanan, R.W., 2005. Voxel-based morphometry versus region of interest: a comparison of two methods for analyzing gray matter differences in schizophrenia. *Schizophr. Res.* 74 (2–3), 135–147. <https://doi.org/10.1016/j.schres.2004.08.019>.
- Good, C.D., Johnsrude, I.S., Ashburner, J., Henson, R.N., Friston, K.J., Frackowiak, R.S., 2001. A voxel-based morphometric study of ageing in 465 normal adult human brains. *NeuroImage* 14 (1 Pt 1), 21–36. <https://doi.org/10.1006/nimg.2001.0786>.
- Hoops, S., Nazem, S., Siderowf, A.D., Duda, J.E., Xie, S.X., Stern, M.B., Weintraub, D., 2009. Validity of the MoCA and MMSE in the detection of MCI and dementia in Parkinson disease. *Neurology* 73 (21), 1738–1745. <https://doi.org/10.1212/WNL.0b013e3181c34b47>.
- Jia, X., Liang, P., Li, Y., Shi, L., Wang, D., Li, K., 2015. Longitudinal study of gray matter changes in Parkinson disease. *AJNR Am. J. Neuroradiol.* 36 (12), 2219–2226. <https://doi.org/10.3174/ajnr.A4447>.
- Job, D.E., Whalley, H.C., McConnell, S., Glabus, M., Johnstone, E.C., Lawrie, S.M., 2003. Voxel-based morphometry of grey matter densities in subjects at high risk of schizophrenia. *Schizophr. Res.* 64 (1), 1–13. [https://doi.org/10.1016/s0920-9964\(03\)00158-0](https://doi.org/10.1016/s0920-9964(03)00158-0).
- Jones, J.D., Kuhn, T.P., Szymkowicz, S.M., 2018. Reverters from PD-MCI to cognitively intact are at risk for future cognitive impairment: analysis of the PPMI cohort. *Parkinsonism Related Disord.* 47 (février), 3–7. <https://doi.org/10.1016/j.parkreidis.2017.12.006>.
- Juh, R., M. Su, C. Lee, T. Suh, O. Nalcioglu. 2006. SU-FF-1-100: investigate between the voxel based morphometry and region of interest study in Alzheimer’s disease. *Med. Phys.* 33 (6Part4): 2020-2020. <https://doi.org/10.1118/1.2240780>.
- Kassubek, J., Juengling, F.D., Hellwig, B., Spreer, J., Lücking, C.H., 2002. Thalamic gray matter changes in unilateral parkinsonian resting tremor: a voxel-based morphometric analysis of 3-dimensional magnetic resonance imaging. *Neurosci. Lett.* 323 (1), 29–32. [https://doi.org/10.1016/s0304-3940\(02\)00111-8](https://doi.org/10.1016/s0304-3940(02)00111-8).
- Krabbe, Katja, Merete Karlsborg, Andreas Hansen, Lene Werdelin, Jesper Mehlsen, Henrik B.W. Larsson, Olaf B. Paulson. 2005. Increased intracranial volume in Parkinson’s disease. *J. Neurol. Sci.* 239 (1): 45-52. <https://doi.org/10.1016/j.jns.2005.07.013>.
- Lee, S.H., Kim, S.S., Tae, W.S., Lee, S.Y., Choi, J.W., Koh, S.B., Kwon, D.Y., 2011. Regional volume analysis of the parkinson disease brain in early disease stage: gray matter, white matter, striatum, and thalamus. *AJNR Am. J. Neuroradiol.* 32 (4), 682–687. <https://doi.org/10.3174/ajnr.A2372>.
- Lewis, Mechelle M., Guangwei, Du., Lee, Eun-Young, Nasralah, Zeinab, Sterling, Nicholas W., Zhang, Lijun, Wagner, Daymond, et al., 2016. The pattern of gray matter atrophy in Parkinson’s disease differs in cortical and subcortical regions. *J. Neurol.* 263 (1), 68. <https://doi.org/10.1007/s00415-015-7929-7>.
- Li, Xingfeng, Xing, Yue, Martin-Bastida, Antonio, Piccini, Paola, Auer, Dorothee P., 2017a. Patterns of grey matter loss associated with motor subscores in early Parkinson’s disease. *NeuroImage: Clinical* 17 (novembre), 498–504. <https://doi.org/10.1016/j.nicl.2017.11.009>.
- Li, Xingfeng, Xing, Yue, Schwarz, Stefan T., Auer, Dorothee P., 2017b. Limbic grey matter changes in early Parkinson’s disease. *Hum. Brain Mapp.* 38 (7), 3566–3578. <https://doi.org/10.1002/hbm.23610>.

- Lisanby, S.H., McDonald, W.M., Massey, E.W., Doraiswamy, P.M., Rozear, M., Boyko, O. B., Krishnan, K.R., Nemeroff, C., 1993. Diminished subcortical nuclei volumes in Parkinson's Disease by MR imaging. *J. Neural Transm. Suppl.* 40, 13–21.
- Luders, E., Gaser, C., Jancke, L., Schlaug, G., 2004. A voxel-based approach to gray matter asymmetries. *NeuroImage* 22 (2), 656–664. <https://doi.org/10.1016/j.neuroimage.2004.01.032>.
- Mak, Elijah, Li, Su., Williams, Guy B., Firbank, Michael J., Lawson, Rachael A., Yarnall, Alison J., Duncan, Gordon W., et al., 2015. Baseline and longitudinal grey matter changes in newly diagnosed Parkinson's disease: ICICLE-PD Study. *Brain: A J. Neurol.* 138 (Pt 10), 2974–2986. <https://doi.org/10.1093/brain/awv211>.
- Marek, Kenneth, Chowdhury, Sohini, Siderowf, Andrew, Lasch, Shirley, Coffey, Christopher S., Caspell-Garcia, Chelsea, Simuni, Tanya, et al., 2018. The Parkinson's progression markers initiative (PPMI) – establishing a PD biomarker cohort. *Ann. Clin. Transl. Neurol.* 5 (12), 1460–1477. <https://doi.org/10.1002/acn3.644>.
- Marreiros, André C., Cagnan, Hayriye, Moran, Rosalyn J., Friston, Karl J., Brown, Peter, 2013. Basal ganglia-cortical interactions in Parkinsonian patients. *NeuroImage* 66 (février), 301–310. <https://doi.org/10.1016/j.neuroimage.2012.10.088>.
- McGregor, Matthew M., Nelson, Alexandra B., 2019. Circuit mechanisms of Parkinson's disease. *Neuron* 101 (6), 1042–1056. <https://doi.org/10.1016/j.neuron.2019.03.004>.
- Mechelli, Andrea, Cathy J. Price, et Karl J. Friston and John Ashburner. 2005. Voxel-based morphometry of the human brain: methods and applications. *Curr. Med. Imaging.* 31 mai 2005. <http://www.eurekaselect.com/60128/article>.
- Mills, Kathryn L., Tamnes, Christian K., 2014. Methods and considerations for longitudinal structural brain imaging analysis across development. *Dev. Cognit. Neurosci.* 9 (juillet), 172–190. <https://doi.org/10.1016/j.dcn.2014.04.004>.
- Nakama, Helenna, Chang, Linda, Fein, George, Shimotsu, Ryan, Jiang, Caroline S., Ernst, Thomas, 2011. Methamphetamine users show greater than normal age-related cortical gray matter loss. *Addiction (Abingdon, England)* 106 (8), 1474–1483. <https://doi.org/10.1111/j.1360-0443.2011.03433.x>.
- O'Neill, Joseph, Schuff, Norbert, Marks, William J., Feiwell, Robert, Aminoff, Michael J., Weiner, Michael W., 2002. Quantitative 1H magnetic resonance spectroscopy and MRI of Parkinson's disease. *Movement Disord.: Official J. Movement Disord. Soc.* 17 (5), 917–927. <https://doi.org/10.1002/mds.10214>.
- Papagno, Costanza, Trojano, Luigi, 2018. In: *Neurological Sciences: Official Journal of the Italian Neurological Society and of the Italian Society of Clinical Neurophysiology*, pp. 215–223. <https://doi.org/10.1007/s10072-017-3154-8>.
- Parkinson Progression Marker Initiative, 2011. The Parkinson Progression Marker Initiative (PPMI). *Prog. Neurobiol.* 95 (4), 629–635. <https://doi.org/10.1016/j.pneurobio.2011.09.005>.
- Pitcher, Toni L., Melzer, Tracy R., MacAskill, Michael R., Graham, Charlotte F., Livingston, Leslie, Keenan, Ross J., Watts, Richard, Dalrymple-Alford, John C., Anderson, Tim J., 2012. Reduced striatal volumes in Parkinson's disease: a magnetic resonance imaging study. *Transl. Neurodegeneration* 1, 17. <https://doi.org/10.1186/2047-9158-1-17>.
- Poewe, Werner, Klaus Seppi, Caroline M. Tanner, Glenda M. Halliday, Patrik Brundin, Jens Volkmann, Anette-Eleonore Schrag, Anthony E. Lang. 2017. *Parkinson Disease. Nature Rev. Disease Primers* 3 (mars): 17013. <https://doi.org/10.1038/nrdp.2017.13>.
- Prange, Stéphane, Metereau, Elise, Maillet, Audrey, Lhommée, Eugénie, Klinger, Hélène, Pelissier, Pierre, Ibarrola, Danielle, et al., 2019. Early limbic microstructural alterations in apathy and depression in de novo Parkinson's disease. *Mov. Disord.* 34 (11), 1644–1654. <https://doi.org/10.1002/mds.27793>.
- Rektorova, Irena, Biundo, Roberta, Marecek, Radek, Weis, Luca, Aarsland, Dag, Antonini, Angelo, 2014. Grey matter changes in cognitively impaired Parkinson's disease patients. *PLoS One* 9 (1), e85595. <https://doi.org/10.1371/journal.pone.0085595>.
- Ritchie, Stuart J., Tucker-Drob, Elliot M., Cox, Simon R., Dickie, David Alexander, Maria del, C., Hernández, Valdés, Corley, Janie, Royle, Natalie A., et al., 2017. Risk and protective factors for structural brain ageing in the eighth decade of life. *Brain Struct. Funct.* 222 (8), 3477–3490. <https://doi.org/10.1007/s00429-017-1414-2>.
- Rubin, Jonathan E., McIntyre, Cameron C., Turner, Robert S., Wichmann, Thomas, 2012. Basal ganglia activity patterns in parkinsonism and computational modeling of their downstream effects. *Eur. J. Neurosci.* 36 (2), 2213–2228. <https://doi.org/10.1111/j.1460-9568.2012.08108.x>.
- Salimi-Khorshidi, Gholamreza, Smith, Stephen M., Nichols, Thomas E., 2011. Adjusting the effect of nonstationarity in cluster-based and TFCE inference. *NeuroImage* 54 (3), 2006–2019. <https://doi.org/10.1016/j.neuroimage.2010.09.088>.
- Stoker, Thomas B., Torsney, Kelli M., Barker, Roger A., 2018. Emerging treatment approaches for Parkinson's disease. *Front. Neurosci.* 12 (octobre) <https://doi.org/10.3389/fnins.2018.00693>.
- Summerfield, Christopher, Junqué, Carme, Tolosa, Eduardo, Salgado-Pineda, Pilar, Gómez-Ansón, Beatriz, Martí, Maria José, Pastor, Pa.u., Ramírez-Ruiz, Blanca, Mercader, José, 2005. Structural brain changes in parkinson disease with dementia: a voxel-based morphometry study. *Arch. Neurol.* 62 (2), 281–285. <https://doi.org/10.1001/archneur.62.2.281>.
- Testa, Cristina, Laakso, Mikko P., Sabatelli, Francesca, Rossi, Roberta, Beltramello, Alberto, Soininen, Hilikka, Frisoni, Giovanni B., 2004. A comparison between the accuracy of voxel-based morphometry and hippocampal volumetry in Alzheimer's disease. *J. Magn. Reson. Imaging* 19 (3), 274–282. <https://doi.org/10.1002/jmri.20001>.
- Tisserand, Danielle J., Pruessner, Jens C., Sanz, Ernesto J., Arigita, Martin P.J., van Boxtel, Alan C., Evans, Jelle Jolles, Uylings, Harry B.M., 2002. Regional frontal cortical volumes decrease differentially in aging: An MRI study to compare volumetric approaches and voxel-based morphometry. *NeuroImage* 17 (2), 657–669.
- Trojano, Luigi, Papagno, Costanza, 2018. In: *Neurological Sciences: Official Journal of the Italian Neurological Society and of the Italian Society of Clinical Neurophysiology*, pp. 53–61. <https://doi.org/10.1007/s10072-017-3155-7>.
- Voormolen, Eduard H.J., Wei, Corie, Chow, Eva W.C., Bassett, Anne S., Mikulis, David J., Crawley, Adrian P., 2010. Voxel-based morphometry and automated lobar volumetry: the trade-off between spatial scale and statistical correction. *NeuroImage* 49 (1), 587–596. <https://doi.org/10.1016/j.neuroimage.2009.07.018>.
- Xia, Jianguo, Miu, Jinlin, Ding, Hongbin, Wang, Xiuping, Chen, Hu.a., Wang, Juan, Juan, Wu., Zhao, Jingli, Huang, Huanxin, Tian, Weizhong, 2013. Changes of brain gray matter structure in Parkinson's disease patients with dementia. *Neural Regener. Res.* 8 (14), 1276. <https://doi.org/10.3969/j.issn.1673-5374.2013.14.004>.
- Zarei, Mojtaba, Ibarretxe-Bilbao, Naroa, Compta, Yaroslau, Hough, Morgan, Junque, Carme, Bargallo, Nuria, Tolosa, Eduardo, Martí, Maria Jose, 2013. Cortical thinning is associated with disease stages and dementia in Parkinson's disease. *J. Neurol. Neurosurg. Psychiatry* 84 (8), 875–881. <https://doi.org/10.1136/jnnp-2012-304126>.