◆ Human Brain Mapping 37:4718–4735 (2016) ◆

New Insights in the Homotopic and Heterotopic Connectivity of the Frontal Portion of the Human Corpus Callosum Revealed by Microdissection and Diffusion Tractography

Alessandro De Benedictis,[1] Laurent Petit,[2] Maxime Descoteaux,[3] Carlo Efisio Marras,[1] Mattia Barbareschi,[4] Francesco Corsini,[5,6] Monica Dallabona,[5,6] Franco Chioffi,[5,6] and Silvio Sarubbo[5,6]*

[1]Department of Neuroscience and Neurorehabilitation, Neurosurgery Unit, Bambino Gesù Children's Hospital – IRCCS, 4 Piazza Sant'Onofrio, Roma, 00165, Italy
[2]Groupe D'Imagerie Neurofonctionnelle, Institut Des Maladies Neurodégénératives - UMR 5293, CNRS, CEA University of Bordeaux, Bordeaux, France
[3]Sherbrooke Connectivity Imaging Lab, University of Sherbrooke, Sherbrooke, Québec, Canada
[4]Department of Histopathology, "S. Chiara" Hospital, Trento APSS – 9 Largo Medaglie D'Oro, Trento, 38122, Italy
[5]Department of Neurosciences, Division of Neurosurgery, "S. Chiara" Hospital, Trento APSS – 9 Largo Medaglie D'Oro, Trento, 38122, Italy
[6]Structural and Functional Connectivity Lab, Division of Neurosurgery, "S. Chiara" Hospital, Trento APSS – 9 Largo Medaglie D'Oro, Trento, 38122, Italy

Abstract: Extensive studies revealed that the human corpus callosum (CC) plays a crucial role in providing large–scale bi-hemispheric integration of sensory, motor and cognitive processing, especially within the frontal lobe. However, the literature lacks of conclusive data regarding the structural macroscopic connectivity of the frontal CC. In this study, a novel microdissection approach was adopted, to expose the frontal fibers of CC from the dorsum to the lateral cortex in eight hemispheres and in one entire brain. *Post-mortem* results were then combined with data from advanced constrained spherical deconvolution in 130 healthy subjects. We demonstrated as the frontal CC provides dense interhemispheric connections. In particular, we found three types of fronto-callosal fibers, having a dorsoventral organization. First, the dorso-medial CC fibers subserve homotopic connections between the homologous medial cortices of the superior frontal gyrus. Second, the ventro-lateral CC fibers subserve homotopic connections between lateral frontal cortices, including both the middle frontal gyrus and the inferior frontal gyrus, as well as heterotopic connections between the medial and lateral frontal cortices. Third, the ventro-striatal CC fibers connect the medial and lateral frontal cortices with the contralateral putamen and caudate nucleus. We also highlighted an intricate crossing of CC fibers with the main association pathways terminating in the lateral regions of the frontal lobes. This combined approach of *ex vivo* microdissection and *in vivo* diffusion tractography allowed demonstrating a previously unappreciated three-dimensional architecture of the anterior frontal CC, thus clarifying the

No one of the authors have conflicts of interest.

*Correspondence to: Silvio Sarubbo, MD, PhD; Department of Neuroscience, Division of Neurosurgery, "Santa Chiara" Hospital, Trento APSS, 9, Largo Medaglie d'Oro, 38122 Trento, Italy.
E-mail: silviosarubbo@gmail.Com

Received for publication 17 April 2016; Revised 12 June 2016; Accepted 26 July 2016.
DOI: 10.1002/hbm.23339
Published online 8 August 2016 in Wiley Online Library (wileyonlinelibrary.com).

© 2016 Wiley Periodicals, Inc.

functional role of the CC in mediating the *inter-hemispheric* connectivity. *Hum Brain Mapp 37:4718–4735, 2016.* © 2016 Wiley Periodicals, Inc.

Key words: corpus callosum; inter-hemispheric connectivity; blunt dissection; tractography; human white matter

INTRODUCTION

The corpus callosum (CC) is the main commissural white matter (WM) tract in the human brain. It provides large-scale integration of sensory, motor and cognitive information between the left and the right hemisphere, at both early and advanced stages of the evolution of the central nervous system (CNS) [Luders et al., 2010]. The CC constitutes an ontogenetic and phylogenetic novelty, since it appears during the development of the placental brain in mammals, without any equivalent precursor in non-placental species. This embryological step allows reducing the distance between the hemispheres, so minimizing the time of interhemispheric transmission [Aboitiz and Montiel, 2003; Mihrshahi, 2006]. Previous studies have demonstrated that the increase of CC thickness occurring during childhood allows the correct maturation of many cognitive and behavioral functions [Hinkley et al., 2012]. Other works have highlighted the crucial role of CC in providing bi-hemispheric interaction in both normal and pathological conditions [Van der Knaap and van der Ham, 2011].

As a consequence, considering the modern "connectomic" view of the brain [Catani et al., 2012a; De Benedictis and Duffau, 2011; Mesulam 1990; Sporns, 2013a,b], a detailed characterization of callosal structural connectivity would be essential to improve knowledge on the bi-hemispheric functional integration of parallel, large-distributed, and integrated neural circuits [Van der Knaap and van der Ham, 2011]. Nevertheless, the exact relationships between the anatomical organization of the CC and its involvement in functional networks have not been extensively investigated in previous studies. Pioneering anatomists of the 19th century found that the CC connects all the cortical convolutions in a homotopic way, with the exception of the olfactory lobe and the temporal pole, which are connected by the anterior commissure [Déjerine, 1892; Meynert, 1888]. Later on, Joseph Klingler introduced a new dissection method allowing a more specific and reliable representation of the human WM anatomy in post-mortem specimens [Klingler, 1935].

The classical anatomical description of the CC was based on early observations in non-human primates, which revealed that interhemispheric fibers originating in different cortical regions cross the midline in specific locations [Pandya and Seltzer, 1986]. Starting from this topographical organization, Witelson [1989] proposed a geometrical antero-posterior compartmentalization of the CC in three portions: the genu, the isthmus and the spelnium. The anterior third, namely the rostrum, the genu, and the rostral body, were assigned to prefrontal, premotor, and supplementary motor areas. Fibers originating in motor and sensory cortices were believed to cross the CC through the anterior and posterior mid-body parts, respectively. Finally, the posterior third, namely the isthmus and the splenium, were attributed to the temporal, parietal, and occipital areas [Witelson, 1989; Aboitz et al., 1992]. For almost 30 years, the vast majority of descriptive anatomy of callosal fibers in humans was based on Witelson's antero-posterior classification. Moreover, as confirmed by more recent studies, the general research on the anatomy of the CC was limited to its most medial or ventral aspects [Chao et al., 2009; Naets et al., 2015; Peltier et al., 2010], without an exhaustive description of the course, terminations and reciprocal connectivity of lateral connections, which remain particularly challenging from both the technical and conceptual points of view.

Nowadays, diffusion tensor imaging (DTI) emerged as the highest-sensitive tool for exploring the human WM, and it radically changed the study of brain functions [Jbabdi et al., 2015]. The application of DTI tractography in CC allowed to confirm the Witelson's topographical mid-sagittal distribution of callosal fibers [Hasan et al., 2008; Hofer and Frahm, 2006; Hofer et al., 2008; Huang et al., 2005]. However, DTI allowed identifying more easily the connections corresponding to the medial cortical areas, and early studies showed a narrow crest aspect of fiber distribution, mostly due to limitations of the simple diffusion tensor model when streamlines merge, branch, or cross. Moreover, pioneering tractography algorithms failed to tract callosal connections when they cross the numerous association and projection pathways forming the corona radiata. Diffusion imaging tractography with constrained spherical deconvolution (CSD) is now able to produce the fan-shaped configuration of tracks, as expected from known anatomy, thus revealing the fiber extension to the lateral parts of cerebral cortex [Farquharson et al., 2013; Tournier et al., 2007].

Interestingly, DTI revealed a prevalent portion of callosal connections within the frontal region [Hofer and Frahm, 2006; Hofer et al., 2008], consistent with the higher density and the lower diameter of callosal fibers in the anterior half of the CC, compared with its posterior half [Aboitiz and Montiel, 2003]. In fact, the frontal lobe is composed of different cortical areas involved in local and widely distributed networks subserving functional integration among many sensory, motor and mnemonic inputs,

10970193, 2016, 12, Downloaded from https://onlinelibrary.wiley.com/doi/10.1002/hbm.23339 by Azienda Provinciale Per I, Wiley Online Library on [08/01/2024]. See the Terms and Conditions (https://onlinelibrary.wiley.com/terms-and-conditions) on Wiley Online Library for rules of use; OA articles are governed by the applicable Creative Commons License

as well as other executive, behavioral, emotional, and language functions [Betzel, 2014; Catani et al., 2012b; De Benedictis et al., 2012]. The subcortical WM architecture of the frontal region, including the U-shaped intergyral fibers, the longer intralobar fibers, and the interlobar bundles, has been investigated by standard *post-mortem* dissection and DTI studies [Catani et al., 2012b; De Benedictis et al., 2012; Martino et al., 2013; Rojkva et al., 2015; Sarubbo et al., 2013]. Nevertheless, the interhemispheric connectivity received less attention in these works.

In this study, we combined standard blunt dissection and an advanced tractography method [CSD particle-filter tracking (PFT) with anatomical priors], to analyze layer-by-layer anatomy of the anterior half of the human CC. In particular, we performed, for the first time to our knowledge, an accurate investigation of WM pathways' course, orientation and reciprocal relationships with other association bundles, by following the fibers from the dorsum of the CC to the lateral cortex of the frontal lobes within both the hemispheres.

MATERIALS AND METHODS

Blunt Microdissection

Eight hemispheres (4 left and 4 right) and one entire human brain were prepared, according to a modified protocol for Klingler's technique [Sarubbo et al., 2015a]. In order to obtain optimal perfusion of the deeper layers of the WM, each specimen was first injected with 10%-formalin solution through the internal carotid arteries and the vertebro-basilar system, and fully immersed in the same solution for 40 days. Then, specimens were frozen at −80°C. Several freezing and de-freezing steps were performed during dissection, in order to obtain the best crystallization process of the formalin solution within the different WM layers.

We exclusively dissected the anterior half of the sagittal extension of the CC, according to the classification of Witelson [1989]. After careful analysis and labeling of the cortical anatomy of the medial and lateral surfaces of the frontal lobes, we started microdissection (×5) by means of wooden spatulas, according to the cortex sparing technique described in our previous studies [De Benedictis et al., 2012, 2014; Sarubbo et al., 2013, 2015a]. After removal of gray matter of the cortical sulci, we dissected the U-fibers of the lateral and medial frontal cortices. Callosal fibers were exposed according to an original layer-by-layer approach, specifically developed for this study. We first dissected the superficial fibers in a medial-to-lateral direction, leaving in situ the posterior part of the superior frontal gyrus (SFG), the middle frontal gyrus (MFG), the inferior frontal gyrus (IFG), and the central lobule, in order to provide additional anatomical landmarks for identifying the relationships between fibers, cortices and deep structures. To show the relationships with other associative bundles, we dissected the superior longitudinal fascicle (SLF) and the arcuate fascicle (AF), the anterior portion of the inferior fronto-occipital fascicle (IFOF) and the cortico-spinal tract (CST). We exposed the region of the striatum to demonstrate its possible relationships with the more ventral CC fibers. During the dissection, we collected sequential pictures.

Finally, in order to describe the homotopic and/or heterotopic origin of callosal fibers exposed during the single-hemisphere dissection, we analyzed the frontal WM bilaterally in one entire brain. The dissection started from the dorsal surface of the anterior half of the CC and proceeded following the fibers in a medial-to-lateral direction in both the hemispheres. The reciprocal connections exposed between the left and right frontal lobes were systematically captured and stored.

Diffusion Imaging and Whole Brain Tractography

In the present study, we used diffusion-weighted and T1-weighted images of 130 healthy right-handed subjects left-lateralized for language (66 females, mean age = 26.2 years, age range = 19–46 years, years of education ≥ 11), who were previously enrolled for the BIL&GIN database [Mazoyer et al., 2016]. All subjects gave written consent to participate in the study, which was approved by the local ethics committee (CCPRB Basse-Normandie).

The diffusion-weighted images were processed using the MRtrix software package (http://www.brain.org.au/software/). First, the diffusion tensor and fractional anisotropy (FA) maps were created. A single fiber response function was estimated from FA values above 0.7 and used as input for constrained spherical deconvolution (CSD) [Descoteaux et al., 2009; Tournier et al., 2007], to compute the fiber orientation distribution functions (fODF) with a spherical harmonic order of 6. The processed datasets (fODF, FA, RGB maps) were upsampled to 1 mm^3 spatial resolution using trilinear interpolation [Girard et al., 2014; Tournier et al., 2012]. Fiber tracking was performed on the upsampled fODF maps using particle-filter tractography with anatomical priors [Girard et al., 2014], creating a whole-brain tractogram (three-dimensional reconstruction of the WM structure) for each subject. Girard et al.'s tracking algorithm is based on a continuous map criterion (CMC) to keep only the streamlines seeded at the white/gray-matter interface and terminating in the gray matter, based on the tissue partial volume estimation maps processed from the subject's T1 image [Girard et al., 2014]. To create the tissue partial volume estimation maps, the T1 was first warped to the diffusion space, using ANTS linear and non-linear registration (http://stnava.github.io/ANTs/). The T1 was segmented into regions of gray matter, WM and cerebrospinal fluid using FSL's (http://www.fmrib.ox.ac.uk/fsl/index.html) fast tool. The partial volume [include and exclude, see Girard et al., 2014] maps were created based on these segmentations. In

10970193, 2016, 12, Downloaded from https://onlinelibrary.wiley.com/doi/10.1002/hbm.23339 by Azienda Provinciale Per I, Wiley Online Library on [08/01/2024]. See the Terms and Conditions (https://onlinelibrary.wiley.com/terms-and-conditions) on Wiley Online Library for rules of use; OA articles are governed by the applicable Creative Commons License

addition to optimizing the stopping criteria, this method uses particle filtering, which applies a backtracking step to find alternative valid pathways to continue the tracking reducing the premature stopping in areas of low anisotropy. Seeding was initiated from the white/gray-matter interface with 10 seeds per voxel. A length threshold was set at a minimum of 10 and maximum of 250 mm. If not otherwise specified, we used the default parameters.

Callosal Fiber Tractography

The Johns Hopkins University (JHU) template [Zhang et al., 2010] was first warped from the standard space to the native diffusion space of each subject through linear and non-linear registration with ANTS. A subset of ROIs was added, including, for each gyral region, its gray matter part and its underlying superficial WM part. All the medial frontal regions of the template, including the SFG, the medial and lateral orbitofrontal areas, and the gyrus rectus (GR) were merged in a single fronto-medial ROI. Both the MFG and the IFG were merged in a single fronto-lateral ROI. These adapted-JHU template ROIs were used to filter the callosal streamlines from the whole tractogram and to determine their cortical termination. From the whole tractogram, we first selected only the streamlines crossing the CC and ending in the frontal cortex, excluding the pre-central gyrus.

Following the same layer-by-layer approach described for post-mortem microdissection, we considered four types of ROIs, namely those within the fronto-medial, fronto-lateral, and mediolateral regions, the CN and the Put, corresponding to the termination territories of callosal fibers (Fig. 7A). We extracted streamlines passing through these structures in either left-to-right or right-to-left direction.

Finally, we applied an outlier removal algorithm [Côté et al., 2015], that used hierarchical QuickBundles clustering [Garyfallidis et al., 2012] to prune anatomical outlier streamlines, namely streamlines "flitting around" a direct CC projection with multiple curves and loops between their frontal or striatal terminations. The cut-off was set at 40% for the cortico-cortical CC streamlines and 35% for the cortico-striatal streamlines. Visualization of the different callosal streamlines and JHU template ROIs were performed with the TrackVis software (http://www.trackvis.org/).

Association Pathways Tractography

In order to show the relationships of fronto-callosal streamlines with associative bundles, we extracted the SLF, AF, and IFOF in a single sample subject. The SLF was composed of frontoparietal streamlines belonging to SLF2 and SLF3, as previously defined [Rojkova et al., 2016], but did not include putative SLF1 streamlines, the existence of which remains to be clarified [Wang et al., 2016]. The AF was composed of both short and long segments, as defined by Rojkova et al. [2016]. The IFOF was defined as frontal streamlines passing through the external capsule and terminating either in the occipital, or in the parietal cortex [Caverzasi et al., 2014].

RESULTS

Blunt Microdissection

All the specimens were regular and homogenous in size and shape. We performed a layer-by-layer dissection of the anterior half of the sagittal extension of the CC, according to the classification of Witelson [1989] (Fig. 1).

Fronto-Callosal Fibers Organization

Following a dorso-ventral progression during the dissection, fibers appeared strongly and progressively intermingled in the most lateral and deepest portion, just before entering the WM of the frontal lobes. In all the eight single hemispheres and in the entire brain, we found three groups of fronto-callosal connections on the dorso-ventral axis. We classified these fibers as dorso-medial, ventro-lateral, and ventro-striatal. The dorso-medial fibers were dissected from the most superficial portion of the frontal CC (Fig. 2). We left in situ the cortex of the cingulate gyrus (CG) to demonstrate the fibers' course on the sagittal plane (Fig. 2A). Then, we identified and exposed all the terminations directed upward, to the medial frontal cortices (Fig. 2B), including motor, premotor, prefrontal, fronto-polar, and medial fronto-basal cortices (Fig. 2C). In all the hemispheres, we found a homogenous and continuous distribution of dorso-medial callosal terminations within the most medial portion of the dorsal tip of the frontal cortices, from the central sulcus (CS) to the GR. Therefore, we proceeded by dissecting callosal fibers passing below the superior frontal sulcus (SFS) (Fig. 3). In order to highlight the relationships of callosal fibers with the cortical structures, we left *in situ* the posterior portions of the SFG, the MFG, the IFG, and the pre-central gyrus (pre-CG) (Fig. 3A). We identified fibers with a typical ventro-lateral course, terminating within the mid-posterior portions of the MFG and the IFG, particularly within the pars opercularis (POp) and the pars triangularis (PTri) (Fig. 3B).

Finally, we identified a third type of fronto-callosal fibers with a more ventral course in the depth of the WM of the IFG, which terminate within the striatal structures (Fig. 4A, B). After removing the insular cortex, we progressively exposed the WM of the anterior third of the external capsule (EC). We dissected the underlying lentiform nucleus (LN), which includes the putamen (Put) laterally, and the globus pallidus (GP) medially, thus separating the EC from the internal capsule (IC). The anteroinferior portion of the Put and the head of the caudate nucleus (CN) are connected by transverse strands of gray matter at the level

10970193, 2016, 12, Downloaded from https://onlinelibrary.wiley.com/doi/10.1002/hbm.23339 by Azienda Provinciale Per I, Wiley Online Library on [08/01/2024]. See the Terms and Conditions (https://onlinelibrary.wiley.com/terms-and-conditions) on Wiley Online Library for rules of use; OA articles are governed by the applicable Creative Commons License

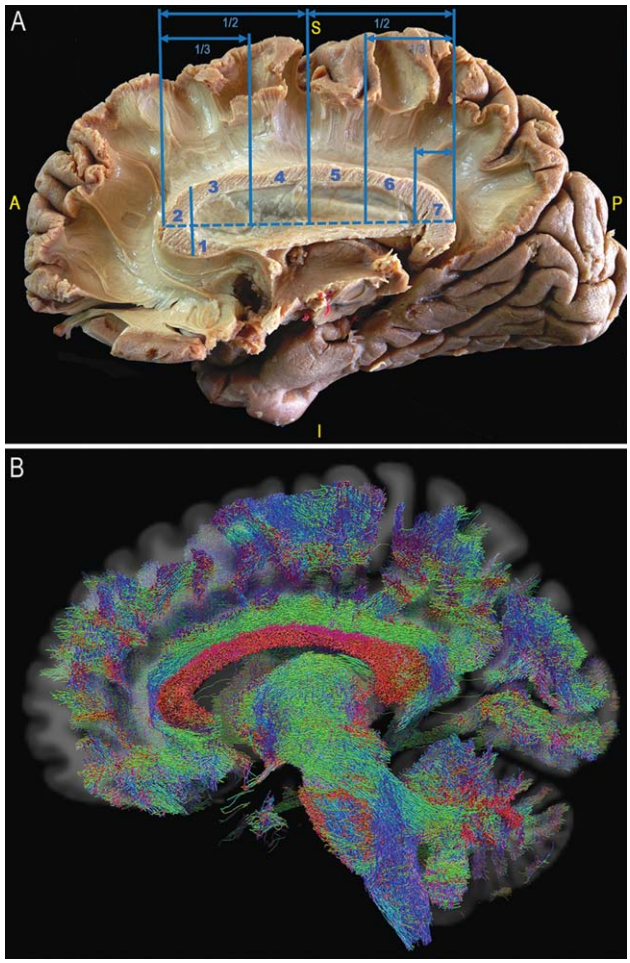

Figure 1.

A. Mid-sagittal dissection of a right hemisphere, showing the organization in subregions, based on the subdivision proposed by Witelson [1989]. Anterior third: Area 1, rostrum; Area 2, genu; Area 3, posterior genu/rostral body. Middle third: Area 4, anterior body; Area 5, posterior body. Posterior third: Area 6, isthmus; Area 7, splenium. **B.** Right hemisphere midsagittal view of the whole-tractogram of a single subject (out of the 130 right-handed subjects), superimposed on the mid-sagittal slice of its anatomical T1 image. The streamlines are colored, according to the classical coding for left/right (red), rostro-caudal (green), and dorso-ventral (blue) mean directions.

of the anterior limb of the IC (Fig. 4C). At this level, we observed thin ventro-striatal CC fibers projecting laterally and deeply to reach the anterior and ventral portion of the Put and the head of the CN (Fig. 4B, C). It is noteworthy that, compared with the dorso-medial and ventro-lateral CC fibers, these ventro-striatal fibers are more strictly intersected over their lateral course with the dorsal CC fibers and with projection fibers directed to pre-central and prefrontal cortices (Fig. 4B).

Bi-hemispheric Organization

The bi-hemispheric dissection of the anterior half of the CC allowed further interesting distinctions (Figs. 5–7). The dorso-medial CC fibers showed a strong homotopic organization, provided by a homogenous and thick bilateral layer of callosal fibers connecting homologous dorsal territories of the SFG, the medial fronto-polar cortices and the GR (Fig. 5A). We also found homotopic ventro-lateral fibers connecting homologous cortices of the posterior third of the MFG and the IFG (particularly, VPMC and POp). Furthermore, we observed heterotopic ventro-lateral fibers connecting the right posterior third of the SFG (particularly, SMA and pre-SMA) and the MFG, with the left ventral and posterior cortices of the IFG (namely, VPMC, POp, and PTri) (Fig. 6).

Continuing the bi-hemispheric dissection of the most ventro-striatal CC fibers, we encountered a strong intersection with the descending projection fibers of the posterior third of the SFG and pre-CG in the portion of the corona radiata. Overpassing this crossing, we followed thin ventral heterotopic CC fibers directly connecting the dorsal and posterior right frontal lobe (namely, SMA, pre-SMA, and posterior third of the MFG) with the left anterior and lateral surface of the head of the CN and the Put (Fig. 5B). Even though these fibers connect the frontal cortex with the contralateral striatal, we considered these connections as heterotopic ventro-striatal CC fibers and not projection fibers, based on their anatomical commissural course.

Tractography of Callosal Fibers

We extracted, from the whole tractograms of 130 subjects, an average of 15,658 ± 3,493 callosal streamlines terminating in the frontal cortex. We identified and mapped three groups of fronto-callosal streamlines, corresponding to the dorso-medial, ventro-lateral, and ventro-striatal fibers observed in our layer-by-layer CC microdissections (Fig. 8).

The dorso-medial streamlines, representing 56.3% ± 8.3% (mean ± standard deviation, $N = 130$) of the fronto-callosal streamlines were U-shaped streamlines connecting homotopically the fronto-medial cortices (Fig. 2D). The ventro-lateral streamlines, 33.9% ± 7.6% of the total fronto-callosal streamlines, were composed of homotopic calloso-lateral streamlines connecting the MFG and the IFG in one hemisphere to their homologues in the other hemisphere (Fig. 3B). The heterotopic callosal medio-lateral streamlines connected the fronto-medial cortex to the opposite fronto-lateral cortex in left-to-right or right-to-left direction. About 17.3% ± 5.0% of the ventro-lateral streamlines, are homotopic, thus a large majority of these streamlines are heterotopic (Fig. 5C). Finally, 9.8% ± 2.7% of the fronto-callosal streamlines were ventro-striatal streamlines connecting either the Put (22.2% ± 9.5%) or the CN

10970193, 2016, 12, Downloaded from https://onlinelibrary.wiley.com/doi/10.1002/hbm.23339 by Azienda Provinciale Per I, Wiley Online Library on [08/01/2024]. See the Terms and Conditions (https://onlinelibrary.wiley.com/terms-and-conditions) on Wiley Online Library for rules of use; OA articles are governed by the applicable Creative Commons License

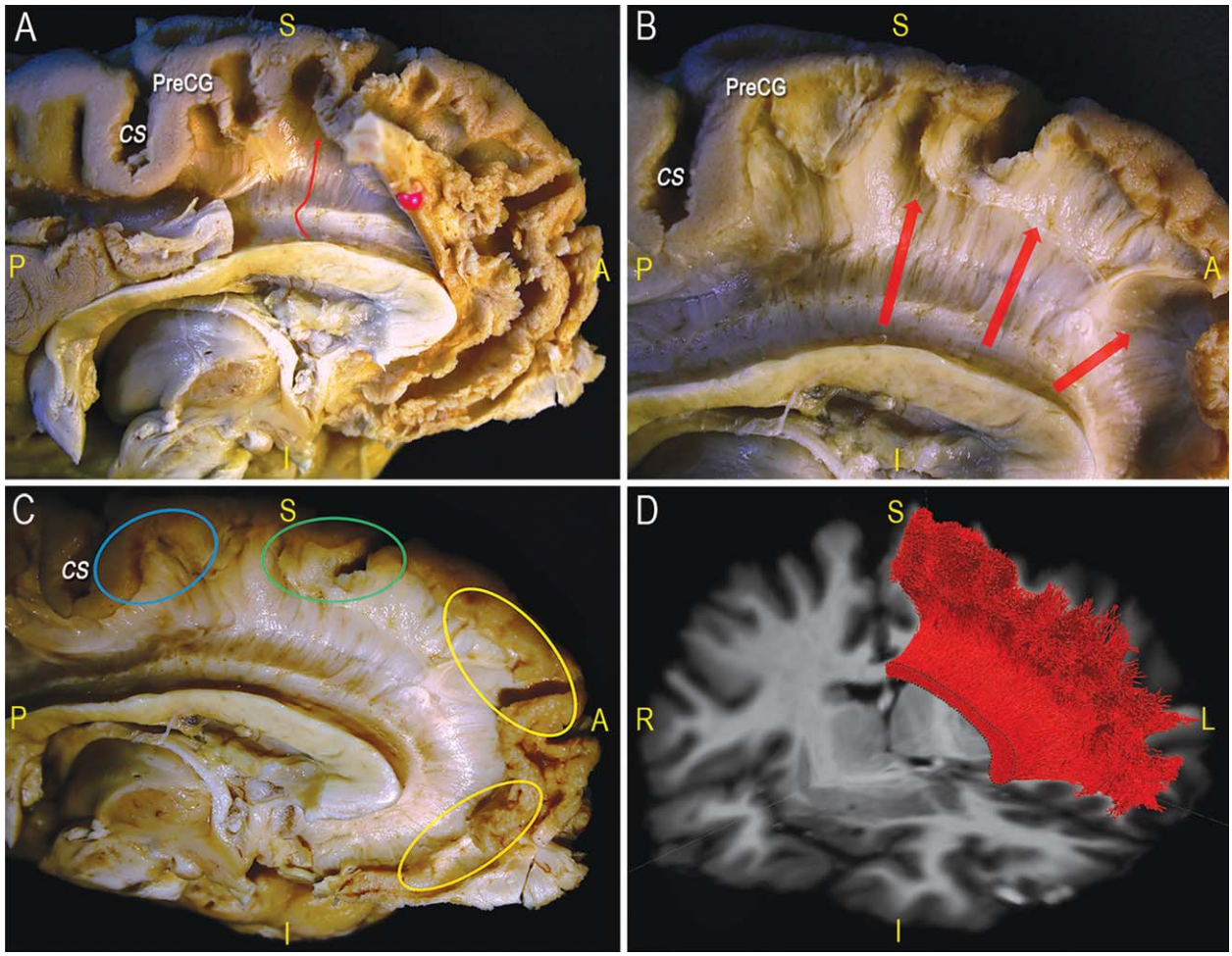

Figure 2.

Dissection of a left hemisphere, showing the dorso-medial callosal fibers. **A.** The dissection started from the superior surface of the anterior part of the CC (red arrow). We lifted the cingulate gyrus (pink pin) and we dissected the fibers. **B.** We exposed the fibers anteriorly to the central sulcus toward the medial surface of the hemisphere (red arrows). **C.** Finally, we showed the cortical districts covered by these dorso-medial frontal fibers, including, from the back to the pole, the central (blue circle), pre-central (green circle), pre-frontal (orange circle), and fronto-basal cortex (yellow circle). **D.** Mid-sagittal view of the dorso-medial streamlines of a single subject, superimposed on its mid-sagittal anatomical T1 image. CS: central sulcus; PreCG: pre-central gyrus. [Color figure can be viewed at wileyonlinelibrary.com]

(77.8% ± 9.5%) to the contralateral frontal cortex in a left-to-right or right-to-left direction (Fig. 4D).

We quantified the dorso-ventral layered distribution of these different types of fronto-callosal streamlines within the body part of the anterior third of the CC (Fig. 9). The homotopic dorso-medial streamlines crossed the inter-hemispheric midline significantly more dorsally than the heterotopic ventro-lateral streamlines, and these latter passed the midline significantly more dorsally than the homotopic ventro-lateral ones (all paired *t*-test of z-coordinates, $P < 0.0001$). In other words, the more lateral are the frontal CC terminations, the more ventrally they cross the interhemispheric midline. It should also be noted that the contralateral ventro-striatal streamlines cross the midline more ventrally in the anterior part than in the posterior part of the CC (Fig. 9).

Relationships with Other Associative and Projective Pathways

We performed a microdissection and tractographic analysis of the relationships between the fronto-callosal fibers and other main association tracts, including the superior

10970193, 2016, 12, Downloaded from https://onlinelibrary.wiley.com/doi/10.1002/hbm.23339 by Azienda Provinciale Per I, Wiley Online Library on [08/01/2024]. See the Terms and Conditions (https://onlinelibrary.wiley.com/terms-and-conditions) on Wiley Online Library for rules of use; OA articles are governed by the applicable Creative Commons License

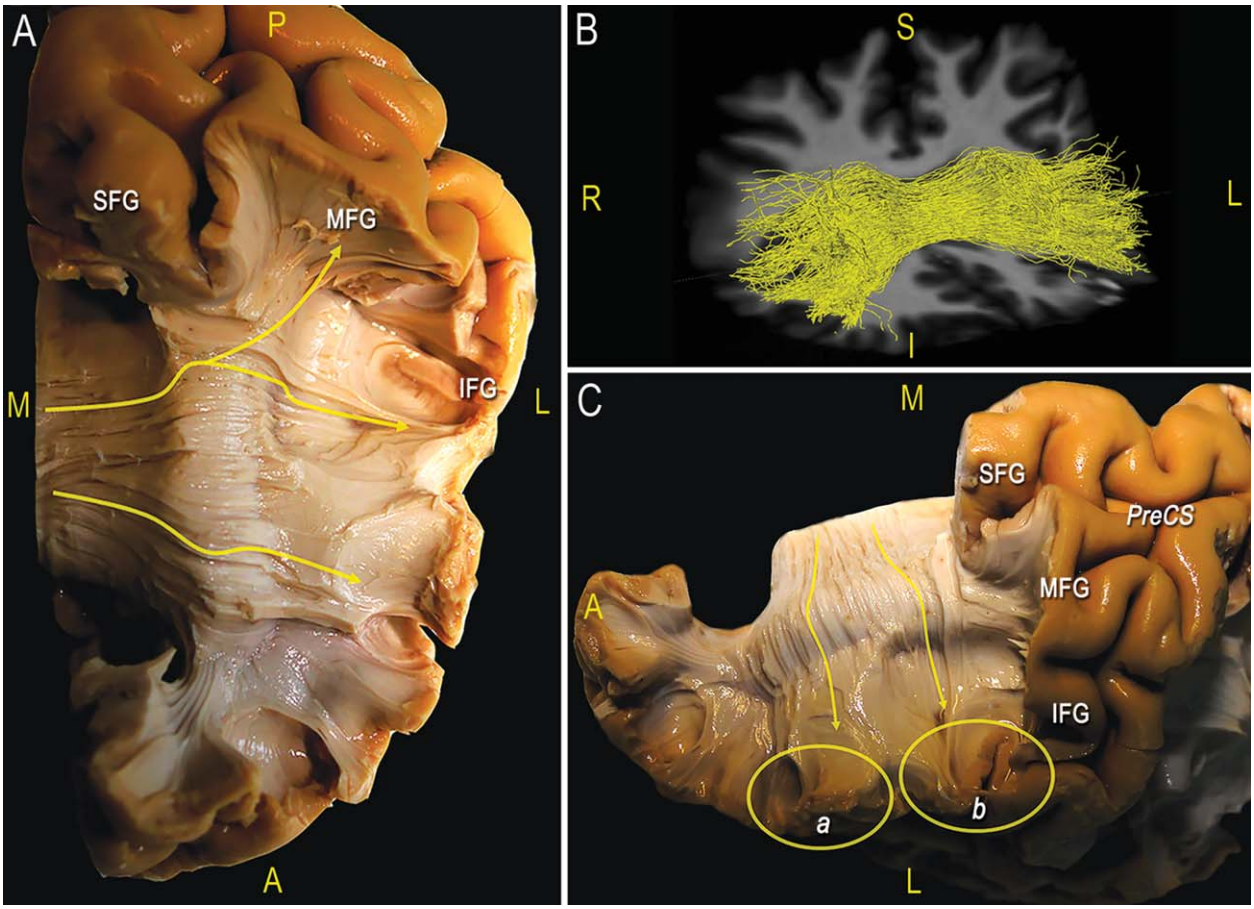

Figure 3.

Dissection of a left hemisphere. **A.** We followed the ventro-lateral callosal fibers, passing below the superior and inferior frontal sulcus and terminating within the MFG and the IFG (yellow arrows). The posterior part of the SFG and MFG were left in situ to show the relationship between the callosal fibers and the cortical structures. **B.** Fronto-anterior view of the ventro-lateral streamlines of a single subject, superimposed on its anatomical T1 image. **C.** Lateral view, showing the course and termination of ventro-lateral CC fibers. We exposed anterior fibers reaching the PTri of the IFG (yellow arrow and circle *a*) and more posterior fibers terminating within the POp of the IFG (green arrow and circle *b*). SFG: superior frontal gyrus; MFG: middle frontal gyrus; IFG: inferior frontal gyrus; pre-CS: pre-central sulcus. [Color figure can be viewed at wileyonlinelibrary.com]

longitudinal fascicle (SLF), the arcuate fascicle (AF) and the inferior fronto-occipital fascicle (IFOF) (Figs. 10 and 11).

The *ex vivo* exposition of the AF started from the temporal region. These fibers surround the posterior limit of the insula with a "C-shaped" course, connecting directly the temporal region to the frontal lobe. In order to highlight the AF relationships with cortical structures of the central region, we left *in situ* the dorsal and ventral pre-central portions of the frontal cortices (Fig. 10A). The fibers of the AF stem have a more superficial horizontal postero-anterior course, compared with the ventro-lateral-striatal group of CC fibers (Figs. 10B and 11). The fronto-parietal component of the SLF runs just laterally to the AF within the frontal region (Fig. 10B).

The IFOF runs through the anterior third of the external capsule to the frontal region with a vertical course. IFOF terminations within the frontal lobe include the fronto-orbital cortices, the frontal pole, the IFG, the MFG and the SFG, as demonstrated by previous blunt dissection and diffusion studies [Caverzasi et al., 2014; Sarubbo et al., 2013]. In this work, we exposed the dorso-lateral and ventral prefrontal cortices (Fig. 10C) and we found strict overlapping between the terminations of ventro-lateral and ventro-striatal callosal fibers and the IFOF (Fig. 10D), particularly in the posterior IFG and in the posterior third of the MFG and the SFG for the ventral and dorsal components of the IFOF, respectively.

Interestingly, we observed a similar crisscross between the ventro-lateral streamlines and the AF, the SLF and the

10970193, 2016, 12, Downloaded from https://onlinelibrary.wiley.com/doi/10.1002/hbm.23339 by Azienda Provinciale Per I, Wiley Online Library on [08/01/2024]. See the Terms and Conditions (https://onlinelibrary.wiley.com/terms-and-conditions) on Wiley Online Library for rules of use; OA articles are governed by the applicable Creative Commons License

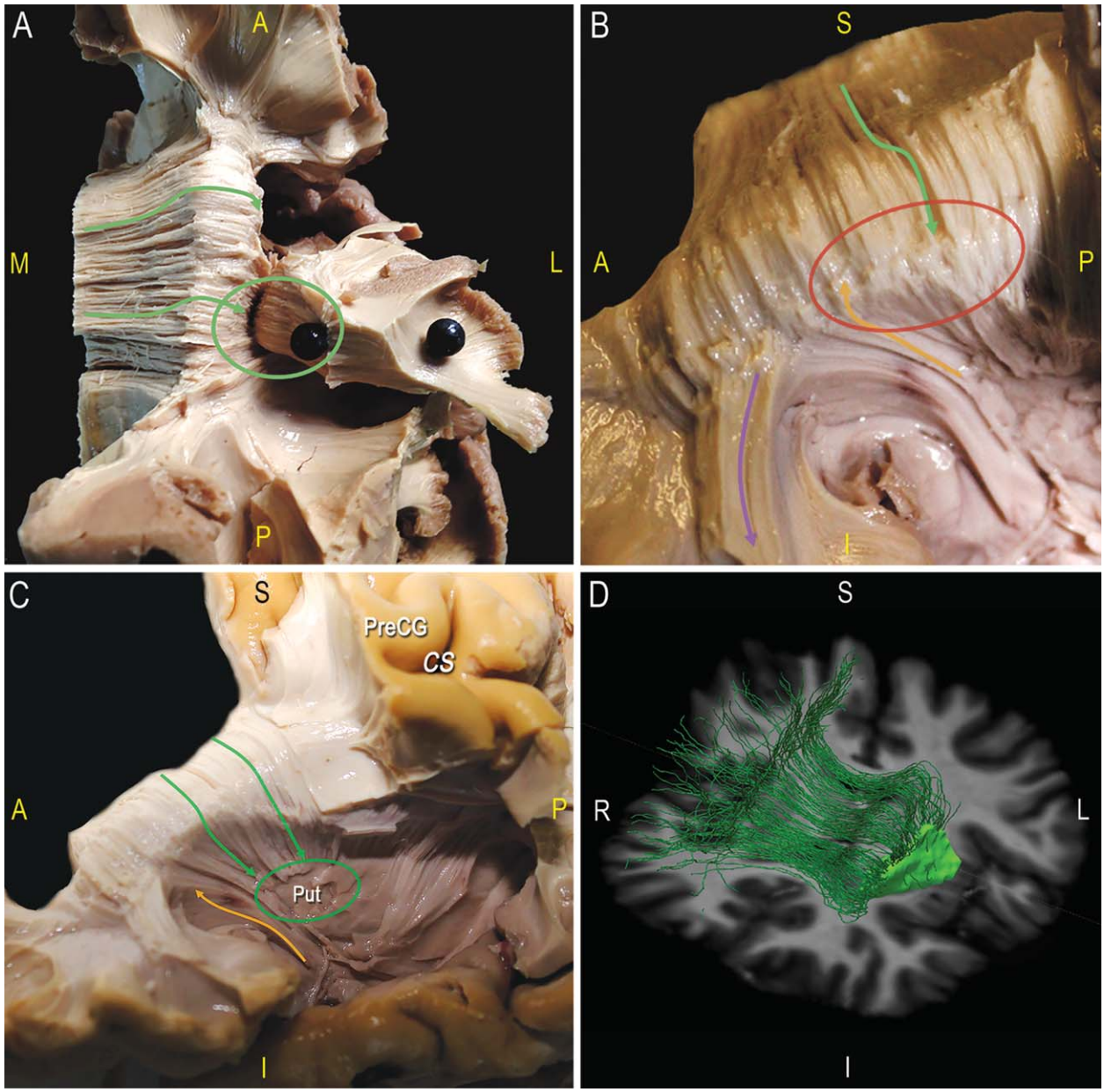

Figure 4.

Ventro-striatal callosal connections. **A.** In this right hemisphere, the medial to lateral course of CC is showed. At the level of the IFG, we identified CC fibers running with a deeper orientation (green arrows). The IFG was cut and laterally lifted (black pins) to better show the fibers course (green circle). **B.** Dissection of a left hemisphere. In order to better analyze the course of these deep ventral fibers, we dissected the basal ganglia region from a lateral view. The IFOF stem was identified at the limen insulae (orange arrow) and a small portion of the AF was also left in situ (violet arrow). The CC fibers cross with IC fibers (red circle), coming from the LN. **C.** After removal of the external capsule, the gray matter of the putamen was exposed (green circle), revealing that callosal fibers are clearly directed to this area. **D.** Fronto-anterior view of the ventro-striatal streamlines terminating in the putamen (in light green) of a single subject superimposed on its anatomical T1 image. CS: central sulcus; PreCG: pre-central gyrus; Put: putamen. [Color figure can be viewed at wileyonlinelibrary.com]

10970193, 2016, 12, Downloaded from https://onlinelibrary.wiley.com/doi/10.1002/hbm.23339 by Azienda Provinciale Per I, Wiley Online Library on [08/01/2024]. See the Terms and Conditions (https://onlinelibrary.wiley.com/terms-and-conditions) on Wiley Online Library for rules of use; OA articles are governed by the applicable Creative Commons License

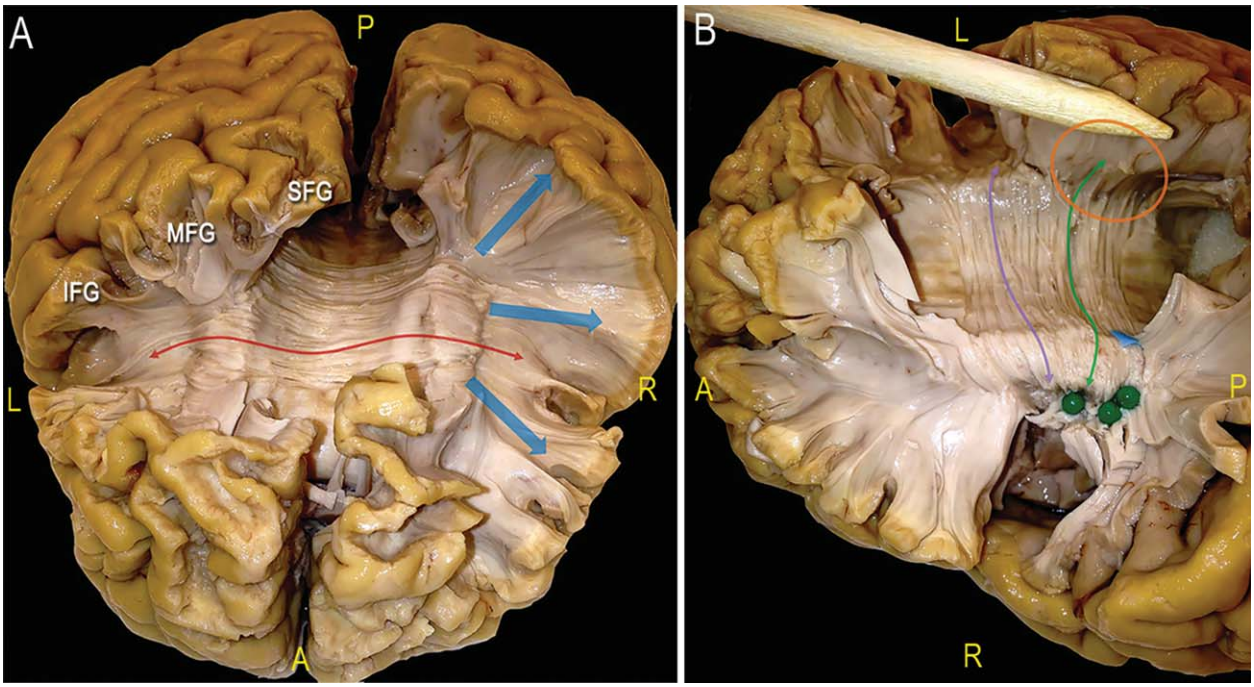

Figure 5.

Dissection of the anterior half of an entire brain. **A.** Dissection of callosal fibers within both the hemispheres (red arrow). On the left side, the superior, middle, inferior cortices were left in situ. On the right side, we exposed the WM of the SFG, MFG, and IFG, to show the lateral distribution of callosal connections (blue arrows). **B.** From this right lateral vision of the left hemisphere of an entire brain, we showed ventro-striatal fibers, coming from the contralateral hemisphere and directed to the basal ganglia region (violet arrow). More posteriorly, we exposed other deep callosal heterotopic connections running below the lateral frontal cortex (blue tag), from the medial part of the SFG (orange circle) to the anterior and lateral surface of the head of CN and Put (green arrow and pins). SFG: superior frontal gyrus; MFG: middle frontal gyrus; IFG: inferior frontal gyrus. [Color figure can be viewed at wileyonlinelibrary.com]

IFOF in *in vivo* tractography (Fig. 11B). Ventro-lateral callosal, SLF and AF streamlines concomitantly terminate in the posterior part of the MFG and the IFG, whereas the IFOF streamlines cross the ventro-lateral callosal bundle deeper in the anterior portion of the corona radiata.

DISCUSSION

In this study, we combined an original post-mortem dissection with an advanced diffusion tractography analysis to describe the structural organization of CC fibers within the frontal region. Recently, traditional microscopic blunt dissection has provided new insights in WM anatomy, confirming and even improving the results of tractography [De Benedictis et al., 2012, 2014; Fernández-Miranda et al., 2015; Martino et al., 2011; Sarubbo et al., 2013]. Despite the high specificity of Klingler's technique in highlighting the course and terminations of long pathways, the main limitations of this approach depend on the progressive removal of the WM. Consequently, even when an accurate layer-by-layer dissection is performed, the sensitivity of this method to study the structural connectivity of the human brain is not comparable to diffusion imaging tractography. For this reason, we integrated and confirmed post-mortem data with the results of a high-reliable diffusion tractography. We adopted a CSD tractography approach, which increased the resolution of crossing/kissing configurations, for example in the case of CC fibers connecting the most lateral parts of the frontal cortex. Furthermore, the particle filtering of tractography algorithm with anatomical prior enabled to improve tracking results by reducing premature stopping through areas of low anisotropy [Girard et al., 2014].

To our knowledge, no microdissection data focusing on the anterior half of the CC, nor a complete bi-hemispheric side-to-side dissection of the CC connections between the frontal lobes were previously reported. In this work, we adopted an original approach following the fibers from the midline, up to the terminal frontal cortices. In all the specimens, we observed that CC fibers constantly follow three main directions, that is, dorso-medial, ventro-lateral, and ventro-striatal. These fibers are characterized by a growing level of reciprocal intersection along their course. In fact, the more the fibers projected laterally and in the depth of the frontal WM, the more they appeared

10970193, 2016, 12, Downloaded from https://onlinelibrary.wiley.com/doi/10.1002/hbm.23339 by Azienda Provinciale Per I, Wiley Online Library on [08/01/2024]. See the Terms and Conditions (https://onlinelibrary.wiley.com/terms-and-conditions) on Wiley Online Library for rules of use; OA articles are governed by the applicable Creative Commons License

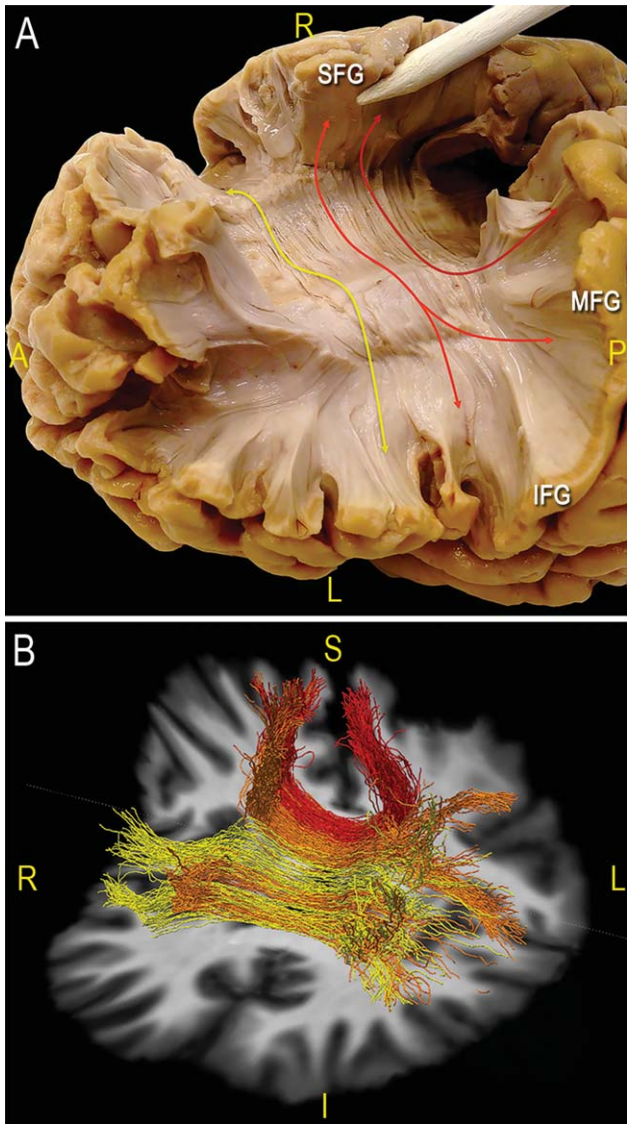

Figure 6.

A, B. Right lateral perspective of an entire brain. Dissection (**A**) and corresponding in vivo tractography (**B**) of callosal fibers having different courses: homotopic dorso-medial fibers, connecting homologous dorsal territories of the SFG (red arrows, red streamlines); heterotopic connections, linking the SFG with the MFG and IFG (orange arrow, orange streamlines); homotopic ventro-lateral fibers, connecting homologous cortices of the posterior third of the MFG and the IFG (yellow arrow, yellow streamlines). SFG: superior frontal gyrus; MFG: middle frontal gyrus; IFG: inferior frontal gyrus. [Color figure can be viewed at wileyonlinelibrary.com]

intermingled with the long-range association pathways, particularly in the depth of the SFS, the MFG, the IFG, and the pre-CG (Figs. 10 and 11).

Moreover, the bi-hemispheric frontal dissection allowed revealing an original widespread branching of heterotopic and homotopic callosal connections. Patterns of homotopic commissural connectivity had already been investigated in non-human primate and human brains, with the aim to define a geometrical calloso-cortical correlation between homologous cortical territories based on cytoarchitectonic similarities [Chao et al., 2009; Hofer et al., 2008; Huang et al., 2005; Park et al., 2008]. More recently, an advanced

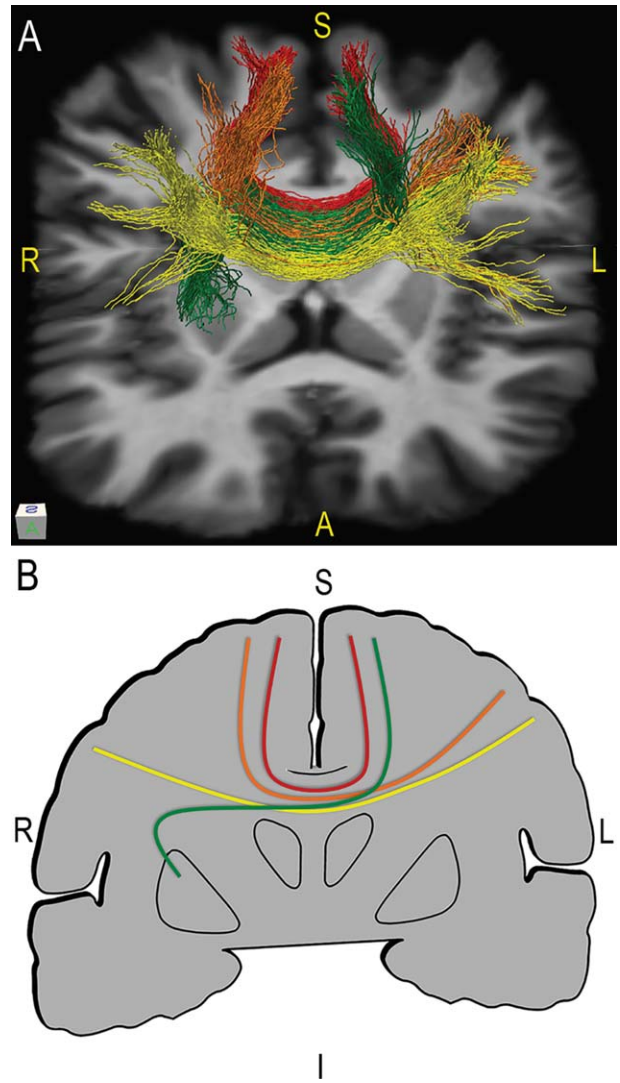

Figure 7.

A, B. Coronal view of in vivo tractography (**A**) and schematic representation (**B**), resuming the different callosal components on the basis of their course and terminations between the two hemispheres: homotopic dorso-medial fibers (in red), heterotopic fibers from the dorso-medial to the contralateral ventro-lateral frontal cortex (in orange), homotopic ventro-lateral fibers (in yellow), ventro-striatal fibers (in green). The four types of callosal streamlines have been cut at different levels along the antero-posterior axis for illustrative purposes. [Color figure can be viewed at wileyonlinelibrary.com]

10970193, 2016, 12, Downloaded from https://onlinelibrary.wiley.com/doi/10.1002/hbm.23339 by Azienda Provinciale Per I, Wiley Online Library on [08/01/2024]. See the Terms and Conditions (https://onlinelibrary.wiley.com/terms-and-conditions) on Wiley Online Library for rules of use; OA articles are governed by the applicable Creative Commons License

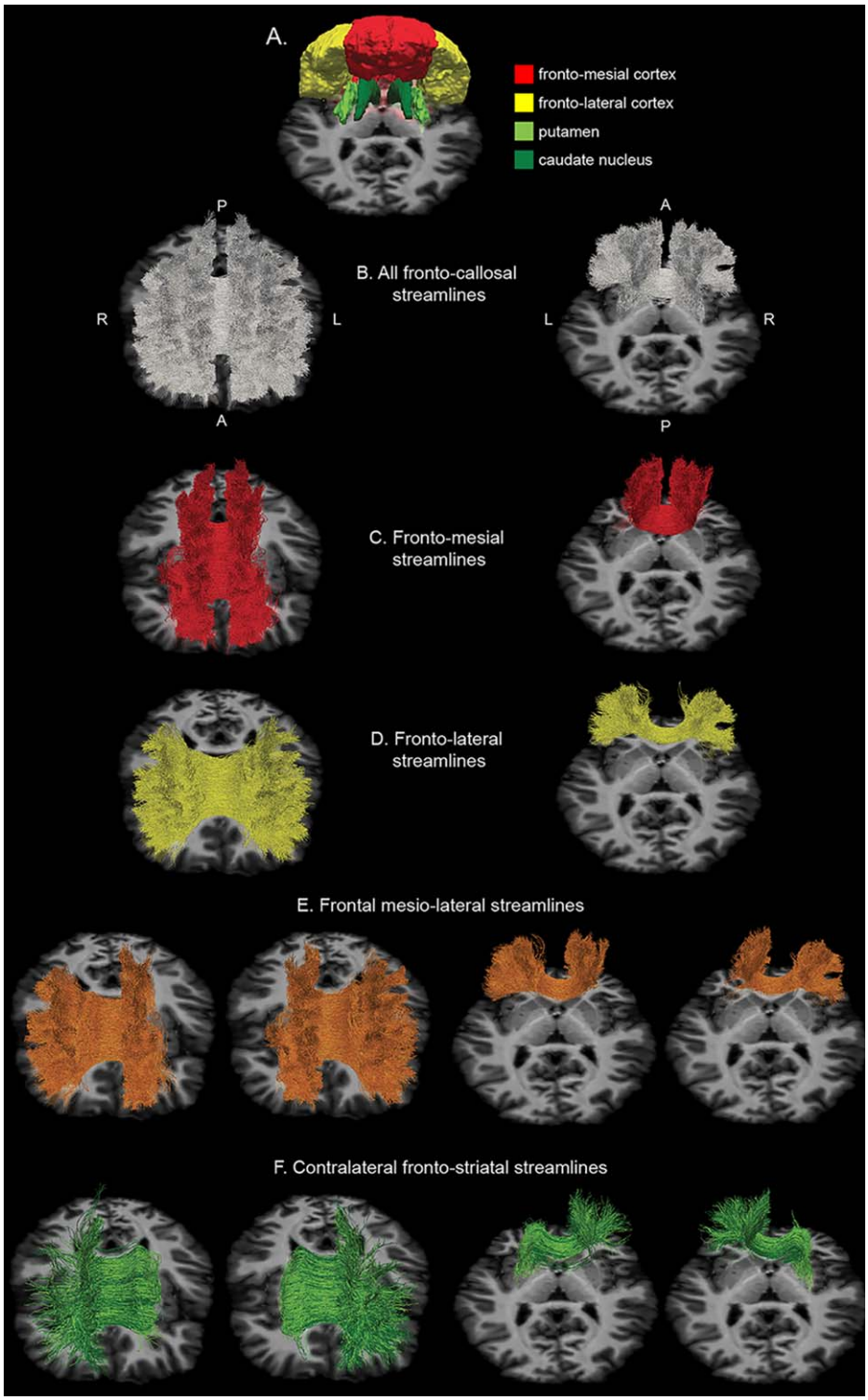

Figure 8.

A. Subset of JHU template ROIs used to extract the fronto-callosal streamlines from the whole-tractogram. ROIs include the fronto-mesial cortex (in red), the fronto-lateral cortex (in yellow), the putamen and the caudate (in green). **B–F.** Example of the different fronto-callosal fibers identified in a single subject. **B.** Anterior (left column) and posterior (right column) views of all the callosal streamlines (in white) passing through the corpus callosum and terminating in the frontal cortex (excluding the pre-central gyrus). **C.** Fronto-medial streamlines (in red). **D.** Fronto-lateral streamlines (in yellow). **E.** Both left-to-right and right-to-left mesio-lateral streamlines (in orange). **F.** Both left-to-right and right-to-left contralateral fronto-striatal streamlines (in green). [Color figure can be viewed at wileyonlinelibrary.com]

10970193, 2016, 12, Downloaded from https://onlinelibrary.wiley.com/doi/10.1002/hbm.23339 by Azienda Provinciale Per I, Wiley Online Library on [08/01/2024]. See the Terms and Conditions (https://onlinelibrary.wiley.com/terms-and-conditions) on Wiley Online Library for rules of use; OA articles are governed by the applicable Creative Commons License

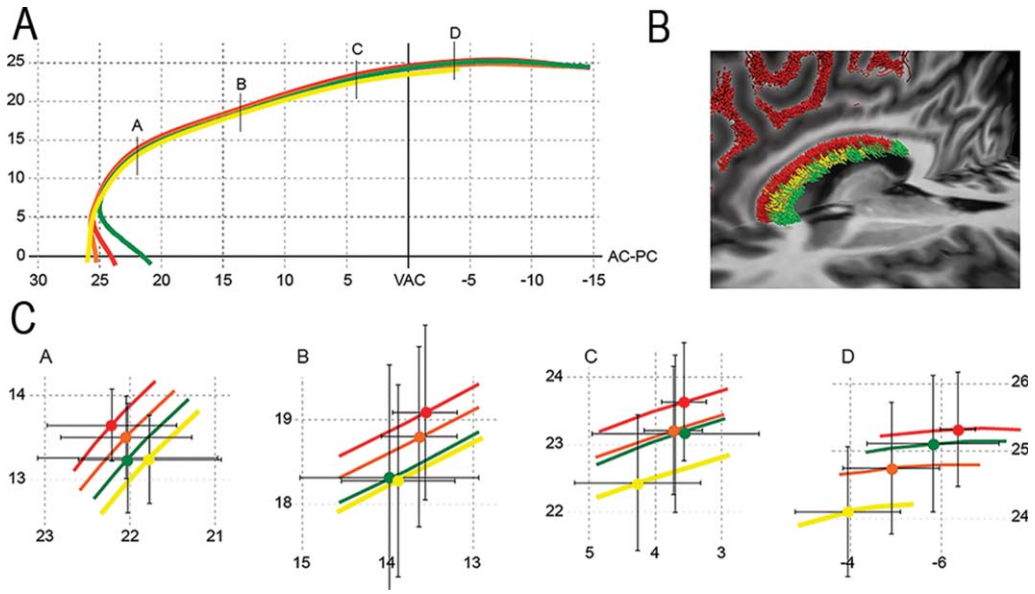

Figure 9.

Mean location of the different types of fronto-callosal streamlines crossing the mid-sagittal plane over 130 right-handed subjects. **A.** Mean topography along the mid-saggital frontal CC of the homotopic dorso-medial (in red) and ventro-lateral (in yellow), heterotopic ventro-lateral (in orange) and ventro-striatal (in green) callosal streamlines in the MNI coordinates space (in mm). **B.** Example of the distribution of the dorso-medial (in red), homotopic and heterotopic ventro-lateral (in yellow) and ventro-striatal (in green) callosal streamlines in a single subject. AC-PC: Bicommissural plane, VAC: Vertical plane passing through the anterior commissure. **C.** Focus on the mean (± standard deviation) topography along the mid-saggital CC for the four types of fronto-callosal streamlines. [Color figure can be viewed at wileyonlinelibrary.com]

high-definition multistage tractography has allowed describing several patterns of interhemispheric connectivity between both cortical and subcortical regions in six human healthy subjects. In the frontal lobe, in addition to an overall prevalent amount of homotopic connectivity, the Authors of this study identified consistent heterotopic connections, especially at the level of the MFG and the pre-central gyrus [Jarbo et al., 2012].

Our dissection data confirmed the interhemispheric reciprocal heterotopic and homotopic CC connectivity between different cortical and subcortical territories (Figs. 5 and 6), in close relationship with the stem of other associative WM pathways (Figs. 10 and 11). The analysis of streamlines, provided by the CSD-PFT tractography completed this observation, showing a more ventral course of fibers crossing the midline and directed to more lateral cortical regions.

This evidence constitutes the anatomical background of the extensive functional involvement of the CC in brain processing and behavior. Several studies have evaluated the effects of CC lesions and diseases in animals and humans, so highlighting the crucial role of the CC in mediating large-scale bi-hemispheric synchronization, integration and coordination between both homologous and heterologous cortical areas [Aralasmak et al., 2006]. Even though this subject is still debated, other Authors previously hypothesized that the CC modulates the hemispheric dominance in response to a given sensori-motor or cognitive task by transferring information and cooperation processes between the left and the right hemisphere through both inhibitory and excitatory stimulation (meta-control phenomenon) [for a review, see Van der Knaap and van der Ham, 2011].

The Dorso-Medial Frontal CC

Dorso-medial fibers are directed to the dorso-medial regions of the whole frontal lobe, providing homotopic connection between homologous fronto-medial areas of both the hemispheres (Fig. 2). Different clinical post-disconnection sequelae have been described after unilateral injury to the medial frontal region, including agonistic and diagonistic dyspraxic motor phenomena between the hands (the so-called "fronto-callosal alien hand") [Scepkowski and Cronin-Golomb, 2003; Tanaka et al., 1996], involuntary mirror image movements [Sarva et al., 2014], and triggering of reaching, grasping and other purposeful movements in the contralateral hand [Goldberg et al., 1981]. These data support the crucial role of frontal premotor inter-hemispheric CC connections in supporting

10970193, 2016, 12, Downloaded from https://onlinelibrary.wiley.com/doi/10.1002/hbm.23339 by Azienda Provinciale Per I, Wiley Online Library on [08/01/2024]. See the Terms and Conditions (https://onlinelibrary.wiley.com/terms-and-conditions) on Wiley Online Library for rules of use; OA articles are governed by the applicable Creative Commons License

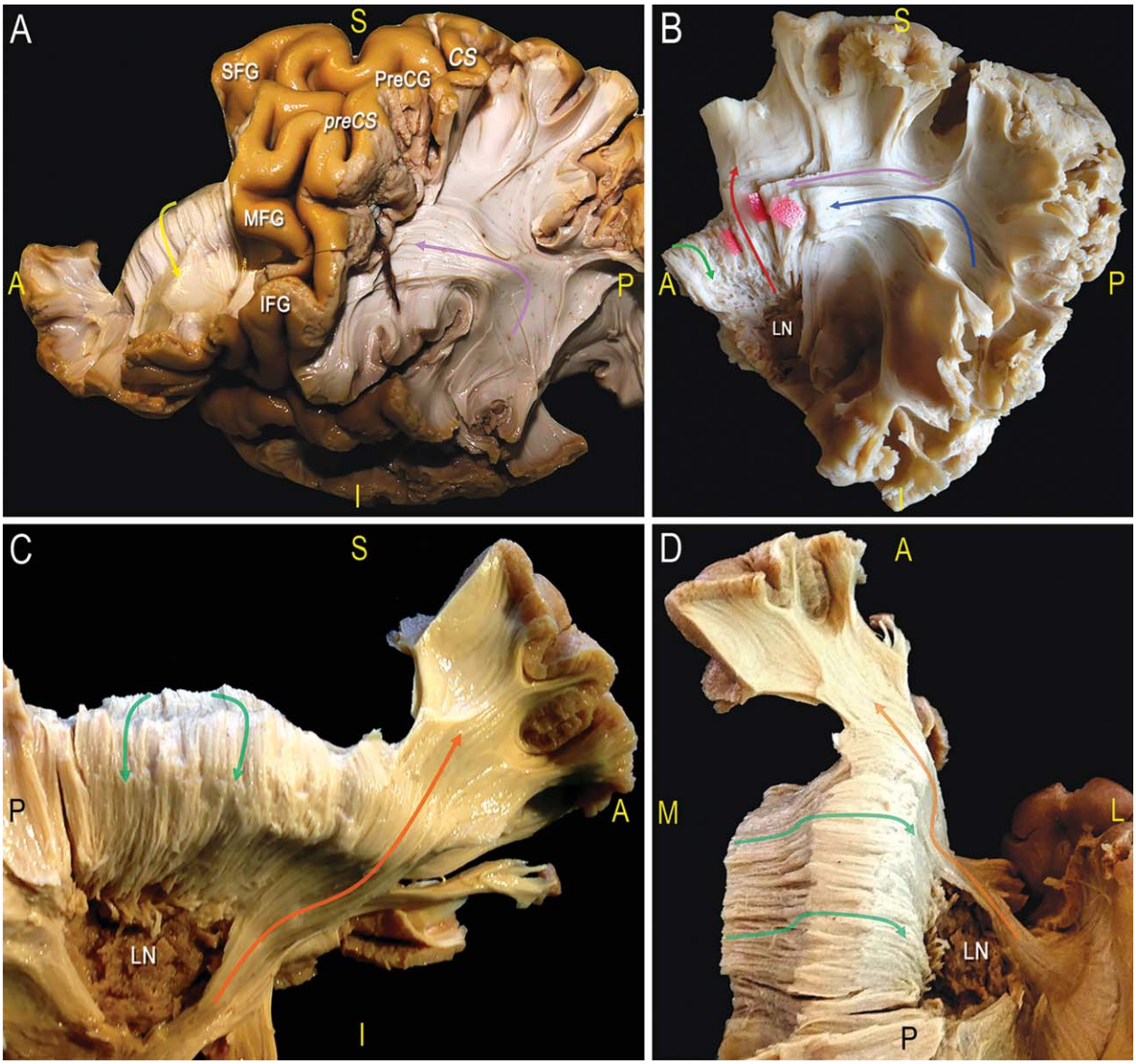

Figure 10.

A, **B**. Dissection of a left hemisphere, showing the relationships between the CC and the AF/SLF complex. **A.** The AF runs from the posterior temporal cortex to the frontal lobe, passing around the posterior part of the insula (violet arrow). The yellow arrow indicates the ventro-lateral CC fibers directed medio-laterally to the IFG. **B.** Section of the hemisphere passing through the head of the caudate nucleus. We demonstrated the layer-by-layer organization of WM pathways (red tags). From the parietal to the frontal region, the following fascicle are visible from the surface to the depth: posterior lateral component of the SLF (pink arrow), AF (violet arrow); cortico-spinal tract (red arrow), which is vertically oriented, in respect to the horizontal SLF fibers. The ventro-striatal fibers (green arrow) run on a deeper level and crosses the fibers forming the internal capsule. **C, D.** Relationships between the anterior third of the CC and the IFOF within a right hemisphere. **C.** The IFOF was exposed starting at the anterior third of the external capsule. Frontal terminations were dissected, in particular those directed to the pre-frontal cortex (orange arrow). Ventro-striatal CC fibers lying on a deeper layer turn ventrally, crossing the internal capsule fibers. **D.** Dissection of the deeper callosal fibers turning towards the basal ganglia region (green arrows). The IFOF runs from the limen insulae with an inferior-to-superior direction, up to the frontal region (orange arrow). SFG: superior frontal gyrus; MFG: middle frontal gyrus; IFG: inferior frontal gyrus; CS: central sulcus; PreCG: pre-central gyrus; PreCS: pre-central sulcus; LN: lenticular nucleus. [Color figure can be viewed at wileyonlinelibrary.com]

10970193, 2016, 12, Downloaded from https://onlinelibrary.wiley.com/doi/10.1002/hbm.23339 by Azienda Provinciale Per I, Wiley Online Library on [08/01/2024]. See the Terms and Conditions (https://onlinelibrary.wiley.com/terms-and-conditions) on Wiley Online Library for rules of use; OA articles are governed by the applicable Creative Commons License

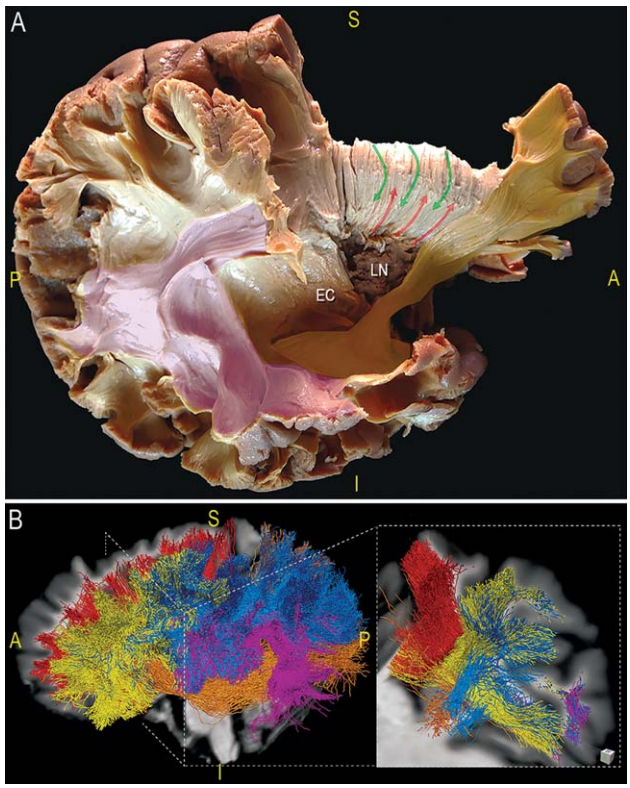

Figure 11.

A. Dissection of a right hemisphere. Pathways have been colored to emphasize the reciprocal relationships between the CC and other associative and projective pathways. The AF runs from the posterior superior and middle temporal cortex to the frontal lobe, describing a C-shaped course around the insula (violet colored area). The frontal cortex has been cut at the level of the CS. The SLF fibers are oriented from posterior-to-anterior within the IFG. After removal of the insular cortex, we considered the anterior two third of the external capsulae. At the level of the limen insulae, we identified the IFOF stem, connecting the temporo-parieto-occipital area with different frontal territories [for a detailed review, see Sarubbo et al., 2013]. In this specimen we exposed the most anterior and deepest component of the IFOF (i.e., vertically oriented) up to the frontopolar and orbital cortex (orange colored area). Posteriorly to the IFOF stem, we dissected the gray matter of the putamen, that is the lateral part of the LN, and the WM fibers forming the internal capsule (red arrows). The deepest layer of the CC has a course from medial to lateral. The ventro-striatal fibers lie on a deeper layer in respect to the IFOF. They cross the IC and turn towards the basal ganglia (green arrows). **B.** Criss–cross between the dorso-medial (in red) and ventro-lateral (in yellow) CC streamlines and the AF (in violet), the SLF (in blue) and the IFOF (in orange) in in vivo single-subject tractography of a left hemisphere. The right inset zooms in on a coronal section (dot line), where the streamlines were cut to emphasize their criss–cross. EC: external capsule; LN: lenticular nucleus. [Color figure can be viewed at wileyonlinelibrary.com]

motor planning, coordination, and control, as well as the CC participation in feedback of sensory signals by inhibiting the opposite hemisphere during simple unimanual movements [Berlucchi, 2012; Geffen et al., 1994].

Additional information on the functional involvement of the dorso-medial callosal connections within pre-frontal regions are limited, probably due to insufficient methodological accuracy. They mostly concern planning, temporal integration, decision making, monitoring, inhibitory control, social cognition, moral judgment, regulation of mood, attention and action [Berlucchi, 2012; Van der Knaap and van der Ham, 2011]. Data on major depression [Ozalay et al., 2013], borderline personality disorders [Walterfang et al., 2010], obsessive compulsive disorders [Di Paola et al., 2013], and autism [Kumar et al., 2010; Paul et al., 2014] have been reported, but an effective correlation between impaired inter-hemispheric connectivity and these disorders has not been clearly demonstrated.

The Ventro-Lateral Frontal CC

We identified a ventro-lateral group of homotopic and heterotopic callosal fibers, directed to the ventral cortices of the frontal lobe, namely the MFG, the IFG and the ventral pre-CG (Fig. 3). This area is crucially involved in language processing, especially within the dominant hemisphere [Sarubbo et al., 2015b; Tate et al., 2014]. Our dissection and tractography data showed, for the first time to our knowledge, that both the SMA/pre-SMA and the POp and PTri of the IFG are connected to the contralateral posterior IFG by heterotopic and homotopic callosal fibers respectively.

We observed a dorso-ventral callosal heterotopy between the left medial and the right lateral frontal cortices (Fig. 6). On the other hand, both *ex vivo* fibers and *in vivo* streamlines appeared to be well-organized, according to a parallel homotopic pattern, along the antero-posterior CC axis (Figs. 7 and 8). Previous works investigated the inter-hemispheric connectivity of the visual cortex and identified a similar structural assessment, including homotopic callosal fibers and heterotopic projections connecting non-homologous areas [Aboitiz and Montiel, 2003; Clarke and Zaidel, 1994; Houzel and Milleret, 1999; Schulte and Müller-Oehring, 2010].

Functional and structural data demonstrated the existence of a dorso-ventral frontal network for language production in the dominant hemisphere [Catani et al., 2012b; Sarubbo et al., 2015b]. Even though this subject has not been extensively analyzed, some Authors advocate an important role of inter-hemispheric connectivity in language. Most of this evidence comes from the analysis of patients affected by CC agenesis (CCA) and disconnection syndromes. These studies demonstrated that the complete or partial absence of CC compromises language maturation [Hines et al., 1992; Larsen et al., 1992]. On the other hand, the positive correlation between language

10970193, 2016, 12, Downloaded from https://onlinelibrary.wiley.com/doi/10.1002/hbm.23339 by Azienda Provinciale Per I, Wiley Online Library on [08/01/2024]. See the Terms and Conditions (https://onlinelibrary.wiley.com/terms-and-conditions) on Wiley Online Library for rules of use; OA articles are governed by the applicable Creative Commons License

performance and CC integrity in preterm born adolescents confirmed the CC participation in language development overall [Thompson et al., 2000], and, particularly, in the lateralization process [Hinkley et al., 2012; Josse et al., 2008]. Moreover, the association between language lateralization, especially within the temporal and frontal regions, and the CC size has been observed after administration of single word naming and semantic decision tasks [Josse et al., 2008].

In this work, we also highlighted the relationships between the fronto-callosal cortical termination and the stem of eloquent WM association pathways crucially involved in language, namely the AF/SLF complex and the IFOF (Figs. 10 and 11). These fascicles subserve the dorsal phonological and the ventral semantic streams of language processing, respectively [Duffau et al., 2014; Martino et al., 2010, 2013]. The high level of structural intersection between SLF and IFOF has been highlighted in previous studies, especially within the frontal region [De Benedictis et al., 2012, 2014; Sarubbo et al., 2013, 2016]. This anatomical feature corresponds also to a strict functional integration, as revealed by direct stimulation data [Ius et al., 2011; Sarubbo et al., 2015a,b] and cortical fMRI analysis [Tate et al., 2014; Vigneau et al., 2006].

Our results suggest that the CC could constitute the structural substrate for further inter-hemispheric integration of language processing. In fact, several neuropsychological studies hypothesized the CC participation in naming objects [Buklina, 2005], phonemic recognition [Temple and Ilsley, 1993], semantic and syntactic processing [Brown et al., 2005; Dennis, 1981; Jeeves and Temple, 1987; Sanders, 1989]. Interestingly, different Authors suggested a possible role of CC in networks subserving higher-levels of communication, including understanding of non-literal language, recognition of affective prosody [Paul et al., 2003], processing of second-order meanings of conversation and events [Shammi and Stuss, 1999], and, just in pediatric subjects, comprehension of meaning of literal language [Brown et al., 2005]. Finally, the significant variability within the sagittal anterior mid-body area between monolingual and bilingual subjects indicates the CC implication in mechanism of language switching by avoiding the interference of one language with the other during speech [Coggins et al., 2004]. In particular, it has been hypothesized that the CC reinforces the articulatory network involved in multiple language capacity, including the pre-central gyrus, the primary motor area and the associative connections to the pre-motor cortex and the SMA [Coggins et al., 2004; Moritz-Gasser and Duffau, 2009].

The Ventro-Striatal Frontal CC

To date, specific subcortical projections of the frontal CC have been rarely reported. The main descriptions concern the contralateral striatum and thalamus [Cummings, 1993; Bonelli and Cummings, 2007; Jarbo et al., 2012] and the claustrum [Cortimiglia et al., 1991; Milardi et al., 2015]. In our specimens, we systematically found callosal fibers with a more ventral orientation, running laterally and ventrally toward the basal ganglia region (namely, to the head of the CN and the Put) (Figs. (4 and 5), and 10). The bi-hemispheric dissection demonstrated a prevalent cortico-striatal connection between the pre-SMA/SMA, the posterior third of the MFG, and the basal ganglia (Fig. 5B). Diffusion tractography data confirmed the course and the reciprocal terminations of these fibers, showing that the postero-dorsal frontal cortices are mainly connected with the anterior and ventral portions of the Put and the CN (Figs. 6C and 7). This is, to our knowledge, the first integrated evidence of a bi-hemispheric cortico-striatal projection pattern within the frontal lobe. These connections may participate in functional interhemispheric recruitment of opposing homotopic and heterotopic regions, which are needed to dynamically balance the hemispheric activation, according to the task demands [Müller-Oehring et al., 2007; Van der Knaap and van der Ham, 2011].

CC and Neural Plasticity

The structural results reported in this study describe a possible anatomical background supporting the role of CC in brain plasticity by mediating the recruitment of contra-hemispheric tracts and cortices, after both acute and slow-progressive lesions [Duffau, 2009], or surgical disconnections [Lassonde et al., 1991; Lessard et al., 2002]. In fact, significant quantitative structural modifications involving the inter-hemispheric connectivity, in particular the body of the CC, have been recently hypothesized as the expression of functional re-organization after ischemic strokes involving motor areas [Li et al., 2015]. In case of slow-growing gliomas located within the rolandic region, fMRI studies reported activations within the contra-lesional primary motor cortex, the pre-motor area and the SMA, reflecting the compensation mechanism of the contralateral hemisphere, likely due to the decrease of transcallosal inhibition [Duffau et al., 2004; Duffau, 2008; Jeeves and Milner 1987].

Regarding language functions, we found callosal connections between homologous territories within the posterior IFG. As largely documented by fMRI and TMS studies, the CC constitutes the structural background for translocation of Broca's area, dorsal and ventral pre-motor territories to the contralateral regions [Desmurget et al., 2007; Duffau, 2008]. Moreover, possible relationships between the CC microstructure and language lateralization have been recently investigated in patients with tumors in the left-dominant hemisphere. The Authors of these studies found a greater value of the CC anatomical microstructure in co-dominant patients, indicating the greater need of excitatory transfer for the compensatory recruitment of non-dominant areas [Tantillo et al., 2016].

10970193, 2016, 12, Downloaded from https://onlinelibrary.wiley.com/doi/10.1002/hbm.23339 by Azienda Provinciale Per I, Wiley Online Library on [08/01/2024]. See the Terms and Conditions (https://onlinelibrary.wiley.com/terms-and-conditions) on Wiley Online Library for rules of use; OA articles are governed by the applicable Creative Commons License

CONCLUSIONS

In this anatomical study, we revisited the three-dimensional architecture of the anterior half of the CC by integrating results of an original layer-by-layer approach during *post mortem* blunt *microdissections* with advanced *in vivo* diffusion tractography.

We demonstrated that the inter-hemispheric connectivity of the frontal region is subserved by a complex, intricate and heterogeneous network of CC fibers. Following the course of these fibers from the CC surface to the termination territories within the lateral cortices, we described three types of fronto-callosal fibers, including: (i) homotopic dorso-medial callosal fibers, connecting the medial frontal areas, (ii) ventro-lateral homotopic and heterotopic fibers, distributed to the ventral cortices of the frontal lobes, and (iii) ventro-striatal heterotopic fibers, connecting the dorsal frontal lobe with the contralateral head of the CN and the Put. We argue that these results highlight more exhaustively the structural background for different functional and plastic properties of brain networks involving the CC.

ACKNOWLEDGMENTS

We thank Graziano Visconti and all the technicians of the laboratory of the Histopathology Unit of the "S. Chiara" Hospital (Trento, Italy) for their irreplaceable support to our work. We are grateful to Ms. Paola Volpi for her precious support in the language revision of this manuscript. We thank Beatrice Paradiso (Cardiopathology Unit, Padua University) for her personal and precious support in the first steps of our lab experience.

REFERENCES

Aboitiz F, Montiel J (2003): One hundred million years of interhemispheric communication: The history of the corpus callosum. Braz J Med Biol Res 36:409e420.

Aboitz F, Scheibel AB, Fisher RS, Zaidel E (1992): Fiber composition of the human corpus callosum. Brain Res 598:143–153.

Aralasmak A, Ulmer JL, Kocak M, Salvan CV, Hillis AE, Yousem DM (2006): Association, commissural, and projection pathways and their functional deficit reported in literature. J Comput Assist Tomogr 30:695–715.

Berlucchi G (2012): Frontal callosal disconnection syndromes. Cortex 48:36–45.

Betzel RF, Byrge L, He Y, Goñi J, Zuo XN, Sporns O (2014): Changes in structural and functional connectivity among resting-state networks across the human lifespan. Neuroimage 102:345–357.

Bonelli RM, Cummings JL (2007): Frontal-subcortical circuitry and behavior. Dialogues Clin Neurosci 9:141–151.

Brown WS, Symingtion M, VanLancker-Sidtis D, Dietrich R, Paul LK (2005): Paralinguistic processing in children with callosal agenesis: Emergence of neurolinguistic deficits. Brain Lang 93: 135–139.

Buklina SB (2005): The corpus callosum. Interhemispheric interactions, and the func- tion of the right hemisphere of the brain. Neurosci Behav Physiol 35:473–480.

Catani M, Dell'acqua F, Bizzi A, Forkel SJ, Williams SC, Simmons A, Murphy DG, Thiebaut de Schotten M (2012a): Beyond cortical localization in clinico-anatomical correlation. Cortex 48:1262–1287.

Catani M, Dell'acqua F, Vergani F, Malik F, Hodge H, Roy P, Valabregue R, Thiebaut de Schotten M (2012b): Short frontal lobe connections of the human brain. Cortex 48:273–291.

Caverzasi E, Papinutto N, Amirbekian B, Berger MS, Henry RG (2014): Q-ball of inferior fronto-occipital fasciculus and beyond. PloS One 9:e100274.

Chao YP, Cho KH, Yeh CH, Chou KH, Chen JH, Lin CP (2009): Probabilistic topography of human corpus callosum using cytoarchitectural parcellation and high angular resolution diffusion imaging tractography. Hum Brain Mapp 3172–3187.

Clarke JM, Zaidel E (1994): Anatomical-behavioral relationships: Corpus callosum morphometry and hemispheric specialization. Behav Brain Res 64:185–202.

Coggins PE, Kennedy TJ, Armstrong TA (2004): Bilingual corpus callosum variability. Brain Lang 89:69–75.

Cortimiglia R, Crescimanno G, Salerno MT, Amato G (1991): The role of the claustrum in the bilateral control of frontal oculomotor neurons in the cat. Exp Brain Res 84:471–477.

Côté M-A, Garyfallidis E, Larochelle H, Descoteaux M (2015): Cleaning up the mess: Tractography outlier removal using hierarchical QuickBundles clustering. 23rd ISMRM Annual Meeting. Toronto, Canada.

Cummings JL (1993): Frontal-subcortical circuits and human behavior. Arch Neurol 50:873–880.

De Benedictis A, Duffau H (2011): Brain hodotopy: From esoteric concept to practical surgical applications. Neurosurgery 68:1709–1723.

De Benedictis A, Sarubbo S, Duffau H (2012): Subcortical surgical anatomy of the lateral frontal region: Human white matter dissection and correlations with functional insights provided by intraoperative direct brain stimulation: Laboratory investigation. J Neurosurg 117:1053–1069.

De Benedictis A, Duffau H, Paradiso B, Grandi E, Balbi S, Granieri E, Colarusso E, Chioffi F, Marras CE, Sarubbo S (2014): Anatomo-functional study of the temporo-parieto-occipital region: dissection, tractographic and brain mapping evidence from a neurosurgical perspective. J Anat 225:132–151.

Déjerine J (1892): Contribution à l'étude de la dégénérescence des fibres du corps calleux. In: Masson, éditeur, Bulletin de la Société de Biologie. Paris (120, boulevard Saint-Germain). p 579–585.

Dennis M (1981): Language in congenitally acallosal brain. Brain Lang 12:33–53.

Descoteaux M, Deriche R, Knosche TR, Anwander A (2009): Deterministic and probabilistic tractography based on complex fibre orientation distributions. IEEE Trans Med Imaging 28: 269–286.

Desmurget M, Bonnetblanc F, Duffau H (2007): Contrasting acute and slow-growing lesions: A new door to brain plasticity. Brain 130:898–914.

Di Paola M, Luders E, Rubino IA, Siracusano A, Manfredi G, Girardi P, Martinotti G, Thompson PM, Chou YY, Toga AW, Caltagirone C, Spalletta G (2013): The structure of the corpus callosum in obsessive compulsive disorder. Eur Psychiatry 28:499–506.

Duffau H (2008): Brain plasticity and tumors. Adv Tech Stand Neurosurg 33:3–33.

Duffau H (2009): Does post-lesional subcortical plasticity exist in the human brain? Neurosci Res 65:131–135.

Duffau H, Khalil I, Gatignol P, Denvil D, Capelle L (2004): Surgical removal of corpus callosum infiltrated by low-grade

10970193, 2016, 12, Downloaded from https://onlinelibrary.wiley.com/doi/10.1002/hbm.23339 by Azienda Provinciale Per I, Wiley Online Library on [08/01/2024]. See the Terms and Conditions (https://onlinelibrary.wiley.com/terms-and-conditions) on Wiley Online Library for rules of use; OA articles are governed by the applicable Creative Commons License

glioma: Functional outcome and oncological considerations. J Neurosurg 100:431–437.
Duffau H, Moritz-Gasser S, Mandonnet E (2014): A re-examination of neural basis of language processing: Proposal of a dynamic hodotopical model from data provided by brain stimulation mapping during picture naming. Brain Lang 131:1–10.
Farquharson S, Tournier JD, Calamante F, Fabinyi G, Schneider-Kolsky M, Jackson GD, Connelly A (2013): White matter fiber tractography: Why we need to move beyond DTI. J Neurosurg 118:1367–1377.
Fernández-Miranda JC, Wang Y, Pathak S, Stefaneau L, Verstynen T, Yeh FC (2015): Asymmetry, connectivity, and segmentation of the arcuate fascicle in the human brain. Brain Struct Funct 220:1665–1680.
Garyfallidis E, Brett M, Correia MM, Williams GB, Nimmo-Smith I (2012): QuickBundles, a method for tractography simplification. Front Neurosci 6:175.
Geffen GM, Jones DL, Geffen LB (1994): Interhemispheric control of manual motor activity. Behav Brain Res 64:131–140.
Girard G, Whittingstall K, Deriche R, Descoteaux M (2014): Towards quantitative connectivity analysis: Reducing tractography biaises. NeuroImage 98:266–278.
Goldberg G, Mayer NH, Toglia JU (1981): Medial frontal cortex infarction and the alien hand sign. Arch Neurol 38:683–686.
Hasan KM, Kamali A, Kramer LA, Papnicolaou AC, Fletcher JM, Ewing-Cobbs L (2008): Diffusion tensor quantification of the human midsagittal corpus callosum subdivisions across the lifespan. Brain Res 1227:52–67.
Hines M, Chiu L, McAdams LA, Bentler PM, Lipcamon J (1992): Cognition and the corpus callosum: Verbal fluency, visuospatial ability, and language lateralization related to midsagittal surface areas of callosal subregions. Behav Neurosci 106:3–14.
Hinkley LB, Marco EJ, Findlay AM, Honma S, Jeremy RJ, Strominger Z, Bukshpun P, Wakahiro M, Brown WS, Paul LK, Barkovich AJ, Mukherjee P, Nagarajan SS, Sherr EH (2012): The role of corpus callosum development in functional connectivity and cognitive processing. PLoS One 7:e39804.
Hofer S, Frahm J (2006): Topography of the human corpus callosum revisited comprehensive fiber tractography using diffusion tensor magnetic resonance imaging. Neuroimage 32:989–994.
Hofer S, Merboldt KD, Tammer R, Frahm J (2008): Rhesus monkey and human share a similar topography of the corpus callosum as revealed by diffusion tensor MRI in vivo. Cereb Cortex 18:1079e1084.
Houzel JC, Milleret C (1999): Visual inter-hemispheric processing: Constraints and potentialities set by axonal morphology. J Physiol Paris 93:271–284.
Huang H, Zhang J, Jiang H, Wakana S, Poetscher L, Miller MI, van Zijl PC, Hillis AE, Wytik R, Mori S (2005): DTI tractography based parcellation of white matter: Application to the mid-sagittal morphology of corpus callosum. NeuroImage 15:195–205.
Ius T, Angelini E, Thiebaut de Schotten M, Mandonnet E, Duffau H (2011): Evidence for potentials and limitations of brain plas- ticity using an atlas of functional resectability of WHO grade II gliomas: Towards a "minimal common brain". Neuroimage 56:992–1000.
Jarbo K, Verstynen T, Schneider W (2012): In vivo quantification of global connectivity in the human corpus callosum. NeuroImage 59:1988–1996.
Jbabdi S, Sotiropoulos SN, Haber SN, Van Essen DC, Behrens TE (2015): Measuring macroscopic brain connections in vivo. Nat Neurosci 18:1546–1555.
Jeeves MA, Milner AD (1987): Specificity and plasticity in interhemispheric integration: Evidence from callosal agenesis. In: Ottoson D, editor. Duality and Unity of the Brain—Unified Functioning and Specialization of the Hemispheres. London: Macmillan. pp 416–441.
Jeeves MA, Temple CM (1987): A further study of language function in callosal agenesis. Brain Lang 32:325–335.
Josse G, Seghier ML, Kherif F, Price CJ (2008): Explaining function with anatomy: Language lateralization and corpus callosum size. J Neurosci 28:14132–14139.
Klingler J (1935): Erleichterung der makroskopischen praeparation des gehirns durch den gefrierprozess. Schweiz Arch Neurol Psychiatr 36:247–256.
Kumar A, Sundaram SK, Sivaswamy L, Behen ME, Makki MI, Ager J, Janisse J, Chugani HT, Chugani DC (2010): Alterations in frontal lobe tracts and corpus callosum in young children with autism spectrum disorder. Cereb Cortex 20:2103–2113.
Larsen JP, Høien T, Ödegaard H (1992): Magnetic resonance imaging of the corpus callosum in developmental dyslexia. Cogn Neuropsychol 9:123–134.
Lassonde M, Sauerwein HC, Chicoine AJ, Geoffroy G (1991): Absence of disconnexion syndrome in callosal agenesis and early callosotomy: Brain reorganization or lack of structural specificity during ontogeny? Neuropsychologia 29:481–495.
Lessard N, Lepore F, Villemagne J, Lassonde M (2002): Sound localizationin callosal agenesis and early callosotomy subjects: Brain reorganization and/or compensatory strategies. Brain 125:1039–1053.
Li Y, Wu P, Liang F, Huang W (2015): The microstructural status of the corpus callosum is associated with the degree of motor function and neurological deficit in stroke patients. PLoS One 10:e0122615.
Luders E, Thompson PM, Toga AW (2010): The development of the corpus callosum in the healthy human brain. J Neurosci 30:10985–10990.
Martino J, Brogna C, Robles SG, Vergani F, Duffau H (2010): Anatomic dissection of the inferior fronto-occipital fasciculus revisited in the lights of brain stimulation data. Cortex 46:691–699.
Martino J, De Witt Hamer PC, Vergani F, Brogna C, de Lucas EM, Vázquez-Barquero A, García-Porrero JA, Duffau H (2011): Cortex- sparing fiber dissection: An improved method for the study of white matter anatomy in the human brain. J Anat 219:531–541.
Martino J, De Witt Hamer PC, Berger MS, Lawton MT, Arnold CM, de Lucas EM, Duffau H (2013): Analysis of the subcomponents and cortical terminations of the perisylvian superior longitudinal fasciculus: A fiber dissection and DTI tractography study. Brain Struct Funct 218:105–121.
Mazoyer B, Mellet E, Perchey G, Zago L, Crivello F, Jobard G, Delcroix N, Vigneau M, Leroux G, Petit L, Joliot M, Tzourio-Mazoyer N (2016): BIL&GIN: A neuroimaging, cognitive, behavioral, and genetic database for the study of human brain lateralization. Neuroimage 124:1225–1231.
Meynert T (1888) Psychiatrie: Clinique Des Maladies Du Cerveau Antérieur Basée Sur Sa Structure, Ses Fonctions Et Sa Nutrition. trans. G. Cousot. Bruxelles: A. Manceaux.
Mesulam MM (1990): Large-scale neurocognitive networks and distributed processing for attention, language, and memory. Ann Neurol 28:597–613.
Mihrshahi R (2006): The corpus callosum as an evolutionary innovation. J Exp Zool B Mol Dev Evol 306:8–17.
Milardi D, Bramanti P, Milazzo C, Finocchio G, Arrigo A, Santoro G, Trimarchi F, Quartarone A, Anastasi G, Gaeta M (2015): Cortical and subcortical connections of the human claustrum revealed in vivo by constrained spherical deconvolution tractography. Cereb Cortex 25:406–414.

10970193, 2016, 12, Downloaded from https://onlinelibrary.wiley.com/doi/10.1002/hbm.23339 by Azienda Provinciale Per I, Wiley Online Library on [08/01/2024]. See the Terms and Conditions (https://onlinelibrary.wiley.com/terms-and-conditions) on Wiley Online Library for rules of use; OA articles are governed by the applicable Creative Commons License

Moritz-Gasser S, Duffau H (2009): Cognitive processes and neural basis of language switching: Proposal of a new model. Neuroreport 20:1577–1580.

Müller-Oehring EM, Schulte T, Raassi C, Pfefferbaum A, Sullivan EV (2007): Local- global interference is modulated by age, sex and anterior corpus callosum size. Brain Res 1142:189–205.

Naets W, Van Loon J, Paglioli E, Van Paesschen W, Palmini A, Theys T (2015): Callosotopy: Leg motor connections illustrated by fiber dissection. Brain Struct Funct Dec 14. [Epub ahead of print].

Ozalay O, Calli C, Kitis O, Cagdas Eker M, Donat Eker O, Ozan E, Coburn K, Saffet Gonul A (2013): The relationship between the anterior corpus callosum size and prefrontal cortex volume in drug-free depressed patients. J Affect Disord 146:281–285.

Pandya DN, Seltzer B (1986): The topography of commissural fibers. In: Leporé F, Ptito M, Jasper HH, editors. Two Hemispheres - One Brain: Functions of the Corpus Callosum. New York: Alan R. Liss, Inc. pp. 47–53.

Park H, Kim JJ, Lee S, Seok J, Chun J, Kim DI, Lee JD (2008): Corpus callosal connection mapping using cortical gray matter parcellation and DT-MRI. Hum Brain Mapp 29:503–516.

Paul LK, Van Lancker-Sidtis D, Schieffer B, Dietrich R, Brown WS (2003): Communicative deficits in agenesis of the corpus callosum: Nonliteral language and affective prosody. Brain Lang 85:313–324.

Paul LK, Corsello C, Kennedy DP, Adolphs R (2014): Agenesis of the corpus callosum and autism: A comprehensive comparison. Brain 137:1813–1829.

Peltier J, Verclytte S, Delmaire C, Deramond H, Pruvo JP, Le Gars D, Godefroy O (2010): Microsurgical anatomy of the ventral callosal radiations: New destination, correlations with diffusion tensor imaging fiber-tracking, and clinical relevance. J Neurosurg 112:512–519.

Rojkova K, Volle E, Urbanski M, Humbert F, Dell'Acqua F, Thiebaut de Schotten M (2016): Atlasing the frontal lobe connections and their variability due to age and education: A spherical deconvolution tractography study. Brain Struct Funct 221:1751–1766.

Sanders RJ (1989): Sentence comprehension following agenesis of the corpus callosum. Brain Lang 37:59–72.

Sarubbo S, De Benedictis A, Maldonado IL, Basso G, Duffau H (2013): Frontal terminations for the inferior fronto-occipital fascicle: Anatomical dissection, DTI study and functional considerations on a multi-component bundle. Brain Struct Funct 218:21–37.

Sarubbo S, De Benedictis A, Milani P, Paradiso B, Barbareschi M, Rozzanigo U, Colarusso E, Tugnoli V, Farneti M, Granieri E, Duffau H, Chioffi F (2015a): The course and the anatomofunctional relationships of the optic radiation: A combined study with 'post mortem' dissections and 'in vivo' direct electrical mapping. J Anat 226:47–59.

Sarubbo S, De Benedictis A, Merler S, Mandonnet E, Balbi S, Granieri E, Duffau H (2015b): Towards a functional atlas of human white matter. Hum Brain Mapp 36:3117–3136.

Sarubbo S, De Benedictis A, Merler S, Mandonnet E, Barbareschi M, Dallabona M, Chioffi F, Duffau H (2016): Structural and functional integration between dorsal and ventral language streams as revealed by blunt dissection and direct electrical stimulation. Hum Brain Mapp 37:3858–3872.

Sarva H, Deik A, Severt WL (2014): Pathophysiology and treatment of alien hand syndrome. Tremor Other Hyperkinet Mov (NY) 4:241.

Shammi P, Stuss DT (1999): Humour appreciation: A role of the right frontal lobe. Brain 122:657–666.

Scepkowski LA, Cronin-Golomb A (2003): The alien hand: Cases, categorizations, and anatomical correlates. Behav Cogn Neurosci Rev 2:261–277.

Schulte T, Müller-Oehring EM (2010): Contribution of callosal connections to the interhemispheric integration of visuomotor and cognitive processes. Neuropsychol Rev 20:174–190.

Sporns O (2013a): Structure and function of complex brain networks. Dialogues Clin Neurosci 15:247–262.

Sporns O (2013b): The human connectome: Origins and challenges. Neuroimage 80:53–61.

Tanaka Y, Yoshida A, Kawahata N, Hashimoto R, Obayashi T (1996): Diagonistic dyspraxia. Clinical characteristics, responsible lesion and possible underlying mechanism. Brain 119: 859–873.

Tantillo G, Peck KK, Arevalo-Perez J, Lyo JK, Chou JF, Young RJ, Brennan NP, Holodny AI (2016): Corpus callosum diffusion and language lateralization in patients with brain tumors: A dti and fmri study. J Neuroimaging 26:224–231.

Tate MC, Herbet G, Moritz-Gasser S, Tate JE, Duffau H (2014): Probabilistic map of critical functional regions of the human cerebral cortex: Broca's area revisited. Brain 137:2773–2782.

Temple CM, Ilsley J (1993): Phonemic discrimination in callosal agenesis. Cortex 29:341–348.

Thompson PM, Giedd JN, Woods RP, MacDonald D, Evans AC, Toga AW (2000): Growth patterns in the developing brain detected by using continuum mechanical tensor maps. Nature 404:190–193.

Tournier JD, Calamante F, Connelly A (2007): Robust determination of the fibre orientation distribution in diffusion MRI: Nonnegativity constrained super-resolved spherical deconvolution. NeuroImage 35:1459–1472.

Tournier J-D, Calamante F, Connelly A, Tournier J-D, Calamante F, Connelly A (2012): MRtrix: Diffusion tractography in crossing fiber regions. Int J Imaging Syst Technol 22:53–66.

Van der Knaap LJ, van der Ham IJ (2011): How does the corpus callosum mediate interhemispheric transfer? A review. Behav Brain Res 223:211–221.

Vigneau M, Beaucousin V, Hervé PY, Duffau H, Crivello F, Houdé O, Mazoyer B, Tzourio-Mazoyer N (2006): Meta-analyzing left hemisphere language areas: Phonology, semantics, and sentence processing. Neuroimage 30:1414–1432.

Walterfang M, Chanen AM, Barton S, Wood AG, Jones S, Reutens DC, Chen J, Velakoulis D, McGorry PD, Pantelis C (2010): Corpus callosum morphology and relationship to orbitofrontal and lateral ventricular volume in teenagers with first-presentation borderline personality disorder. Psychiatry Res 183:30–37.

Wang X, Pathak S, Stefaneanu L, Yeh FC, Li S, Fernandez-Miranda JC (2016): Subcomponents and connectivity of the superior longitudinal fasciculus in the human brain. Brain Struct Funct 221:2075–2092.

Witelson SF (1989): Hand and sex differences in the isthmus and genu of the human corpus callosum. A postmortem morphological study. Brain 112:799–835.

Zhang Y, Zhang J, Oishi K, Faria AV, Jiang H, Li X, Akhter K, Rosa-Neto P, Pike GB, Evans A, Toga AW, Woods R, Mazziotta JC, Miller MI, van Zijl PCM, Mori S (2010): Atlas-guided tract reconstruction for automated and comprehensive examination of the white matter anatomy. NeuroImage 52:1289–1301.

10970193, 2016, 12, Downloaded from https://onlinelibrary.wiley.com/doi/10.1002/hbm.23339 by Azienda Provinciale Per I, Wiley Online Library on [08/01/2024]. See the Terms and Conditions (https://onlinelibrary.wiley.com/terms-and-conditions) on Wiley Online Library for rules of use; OA articles are governed by the applicable Creative Commons License